

Amniotic Membrane as Allograft for Construction of Neovagina by McIndoe Technique in Vaginal Agenesis

Necip Cihangir Yılanlıoğlu¹, Altuğ Semiz¹, Yaşam Kemal Akpak² & Semra Kahraman³

¹ Department of Obstetrics and Gynaecology, Istanbul Memorial Hospital, Istanbul, Turkey

² Dışkapı Yıldırım Beyazıt Education and Research Hospital, Department of Obstetrics and Gynaecology, Ankara, Turkey

³ Assisted Reproductive Technologies and Genetics Centre, Istanbul Memorial Hospital, Istanbul, Turkey

Correspondence: Yaşam Kemal AKPAK, MD, Dışkapı Yıldırım Beyazıt Education and Research Hospital, İrfan Baştuğ St., Dışkapı, Department of Obstetrics and Gynaecology, Ankara 06110, Turkey. Tel: 90-533-487-6138. Fax: 90-312-222-0583. E-mail: yasamaster@gmail.com

Received: May 11, 2016 Accepted: October 8, 2016 Online Published: October 26, 2016

doi:10.5539/gjhs.v9n4p31

URL: <http://dx.doi.org/10.5539/gjhs.v9n4p31>

Abstract

Background: To assess the anatomical and functional results of neovagina creation with amniotic membrane.

Methods: We operated on three young women with vaginal agenesis two of whom had a diagnosis of Mayer-Rokitansky-Küster-Hauser (MRKH) syndrome and the other mixed gonadal dysgenesis. The mean age was 29.67 years (range 28-33). A fresh amniotic membrane retrieved from a Cesarean section on the same operation date was prepared over a mould and inserted into the newly formed tunnel between the bladder and the rectum as per McIndoe technique. The patients were followed up for one year minimum.

Results: Mean vaginal depth achieved was 8, 10 and 7 cm (average 8.3 cm) at the 12 month follow-up clinic. Two patients expressed having satisfactory sexual life at follow-up interview. One patient who had infrequent coitus and neglected appropriate use of mould needed further follow-up in clinic and self-dilation.

Conclusions: McIndoe vaginoplasty with fresh-homologous amniotic membrane is an effective low-risk procedure. It can produce good results in fairly short time span with modest demand on patient compliance and rare morbidity.

Keywords: vaginal reconstruction, mayer-rokitansky-küster-hauser, vaginoplasty, genital tract abnormality, müllerian agenesis, neovagina

1. Introduction

Congenital absence (agenesis or atresia) of the vagina is encountered with a frequency of 1 in 4.000 to 5.000 (Raga et al., 1997). The condition is associated most commonly with Mayer-Rokitansky-Kuster-Hauser (MRKH) syndrome and androgen insensitivity (AIS) syndrome. Much less often, as in one of our cases presented, the disorder may be part of a complex chromosomal defect like mixed gonadal dysgenesis as well as in isolation. The treatment should provide not only an anatomically acceptable result from the viewpoint of the surgeon but also a satisfactory sexual experience on the part of the patient and the spouse/partner. This in turn involves the timing and the time length between the decision to have the condition treated and the onset of a satisfactory sexual life. Although there is no consensus on “the best”, methods of nonsurgical options like gradual self-dilatation (Frank dilators and derivatives) and relatively conservative surgery such as laparoscopic Vecchiotti procedure are generally considered safer procedures amongst a plethora of vaginoplasty techniques (Callens et al., 2014). Construction of a neovagina utilising amniotic membrane is in fact has a long history, first record of which dates back to 1934 (Brindeau, 1934). There are some considerable advantages of this approach like vaginal-only approach, lack of need for obtaining graft from some other part of the body (split thickness grafts) avoiding scars, high rate of graft take, no intervention with other organs or systems (like bowel anastomosis) and rather short time span before sexual activity may begin (usually six weeks after the operation). The potential risks of rectal and vesical injury aside, the main drawback is stenosis or contracture, common to all types of grafts utilised in McIndoe procedures. (skin, amnion, interceding adhesion barriers, buccal mucosa). In the review by Callens et al. the analysis of 9 studies reporting Modified McIndoe procedure with amnion, 97% of the total patient sample resulted in normal

epithelization of the vagina and 7 or more centimeters of vaginal depth. In some other series not included in that review but referred in this article (Morton & Dewhurst, 1986: 27 cases; Sharma, Dahiya, Chechi, & Sirohiwal, 2008: 17 cases; Bleggi-Torres, Werner, & Piazza, 1997: 10 cases) the anatomical success rate (defined as depth \geq 8 cm and easy two finger insertion) stands at 88% to 100%. In an extensive review by Callens et al., 2014, the authors conclude that although the literature lacks high quality comparative outcome studies, because of the low physical complication rate and an overall success chance of 75% (anatomical success defined as \geq 7cm depth and functional success as coitus) vaginal dilation procedures seem to be justified as a first choice. Surely each patient must be handled elaborately regarding their own, deservedly unique case. A sexually inexperienced patient with only a few months towards a marriage can hardly settle with a method which requires her labour and patience over a lengthy time span to achieve a satisfactory result. The technique we describe here is in accordance with the demands of patients applying for treatment in similar conditions.

2. Materials and Methods

Three patients aged 28, 28 and 33 were operated on between the years 2007 and 2015. Two of them were married and one had the operation 3 months before the wedding date. They were adequately examined and put through clinical and laboratory tests to confirm the aetiology and any other disorders likely to accompany their condition - complete agenesis of the vagina. Table 1 summarises relevant clinical data. Written consent was obtained from the patient and the spouse. Verbal consent only have been obtained from the patients who donated the amniotic membranes after their Cesarean delivery. Approval of the "Ethics Committee of Sisli Memorial Hospital" has been obtained for the operations subject to the study.

Table 1. Relevant clinical data

Case / Age	Examination	Diagnostic procedures	Karyotype : Diagnosis
Patient 1/ 33 years old	No uterus, normal ovaries, vaginal agenesis	MRI: No uterus, normal ovaries	46 XX: Mayer-Rokitansky-Küster-Hauser Syndrome (MRKH)
Patient 2/ 28 years old	No internal organs, vaginal agenesis	Ultrasound Scan + MRI: No uterus or ovaries, ovoid tissues in each inguinal canal	45XO/46XY: Mixed Gonadal Dysgenesis
Patient 3/ 28 years old	No uterus, normal ovaries, vaginal agenesis	Laparoscopy: No uterus, normal ovaries	46XX: Mayer-Rokitansky-Küster-Hauser Syndrome (MRKH)

MRI: Magnetic Resonance Imaging.

None of the patients had associated renal-urinary tract abnormalities. Patient 1 had familial Mediterranean fever, on colchicine. Patient 2 who had mixed gonadal dysgenesis had previously undergone an operation for removal of the gonads (pathology: benign testis tissue) retained in the inguinal canal. She also had mild osteoporosis and was on estrogen (Premarin 0.625 mg daily) and calcium daily. Patient 3 had no other health problem.

The operations were scheduled to take place on the same date with, and only a few hours after, a Cesarean section. The mothers to have the Cesarean were screened preoperatively for human immunodeficiency virus, hepatitis B virus and hepatitis C virus. According to the Committee on Microbiological Safety of Blood and Tissues for Transplantation (1996), cytomegalovirus and toxoplasma screens are not deemed necessary for tissue transplantation but these latter tests had been done during the antenatal clinics already.

The amniotic membrane graft was prepared by retrieving the maximum area possible, peeling all layers off of the fetal surface of the placenta as well (Figure 1). The amniotic membranes were then separated from the chorionic layers, washed and placed in dilute povidone-iodine and saline solution (Figure 2).

The recipient patient was then operated on to form the vaginal tunnel for the graft. Under general anesthetic and in lithotomy position with urinary catheter in situ, a 3 cm transverse incision was made at the perineum where there is a shallow pouch or when the perineum is virtually flat, two slight dimples can be seen and felt (Figure 3). These dimples are the lower ends of the vestigial müllerian ducts. These are deepened after the initial traversing incision by mainly blunt finger or Hegar dilators up along between the rectum and bladder, to secure a depth of 11-12 cm. This way two parallel tunnels are formed with a thin septum in between. This septum is incised with scissors either

in steps as the dissection is made or after the tunnels are sufficiently formed, to form a single space with adequate width and depth (Figure 4). Bipolar cautery is used for hemostasis. A finger may be placed in the rectum during the process if felt necessary. This technique is referred to as Sheare's method (Chakrabarty, Mukhopadhyay, & Mukherjee, 2011).

The newly created vaginal space is packed with hot-water (50 °C) soaked gauze and the graft prepared on mould as follows. A 5 mm thick sponge sheet is cut and formed into a hood to fit over the mould modeled from dental (polymethyl methacrylate) material. The mould is tubular shape, 10.5 cm long with a perforated base plate and 3 cm in diameter. Four canals were carved along the mould to allow drainage (Figure 5) .

This type of mould was used in our first two cases and was replaced with a teflon one in the third case for smoother shaping but similar size. (Figure 6). A condom was then rolled on the sponge-covered mould. Several holes were made in the condom with a green needle (21 Gauge) to let exudation get absorbed by the foam and drain along the grooves (Figure 7). The amnion sheet is spread over a layer of tulle gras and "scored" (stabbed with No.11 scalpel blade making 2-3 holes in its each square centimeter). When slightly stretched it should display a "meshed" appearance showing tiny holes. It is then wrapped around the prepared mold (tulle gras side on condom) and sutured edge-to-edge from the tip to the base with interrupted 3/0 monocryl sutures. The contact between the tulle gras and condom/mould complex must be loose enough to allow some movement. The excess amnion/tulle gras is cut off . The graft thus prepared is then inserted in the vaginal space and sutured to the inner sides of the labia majora through the base holes of the mould (avoiding the fragile labia minora) (Figure 8). The patients were hospitalized for 7 days: All spent the first 5 days on bedrest and the moulds were removed on the 10th, 10th and 7th days in case order. The patients were asked to use the moulds (the same ones used at the operation) for six weeks at night and during the day as much as possible. The whole length (approximately 160-170cm) of the tubing of a pediatric intravenous infusion set was found practical and easy to use, threaded through the holes of the mould and tied around the waist. Estriol cream (0.1% estriol) was prescribed for use before reinsertion. After that period the mould was advised to be used at night only if there would be no regular intercourse.

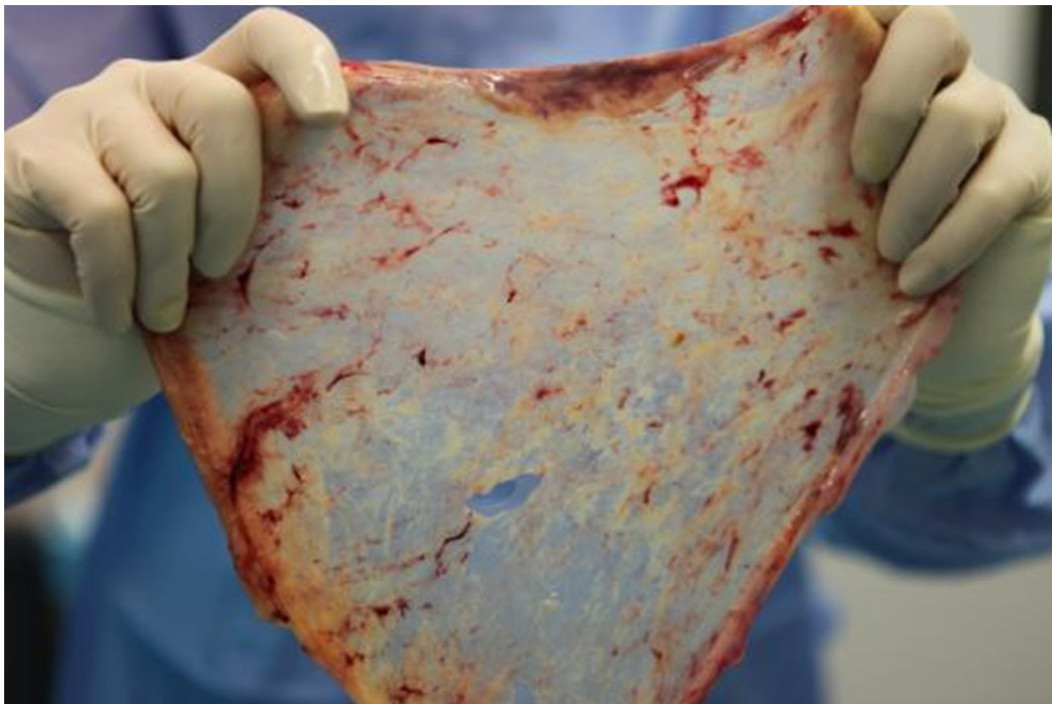


Figure 1. Fetal membranes peeled off the placental fetal surface to provide an area as wide as possible.

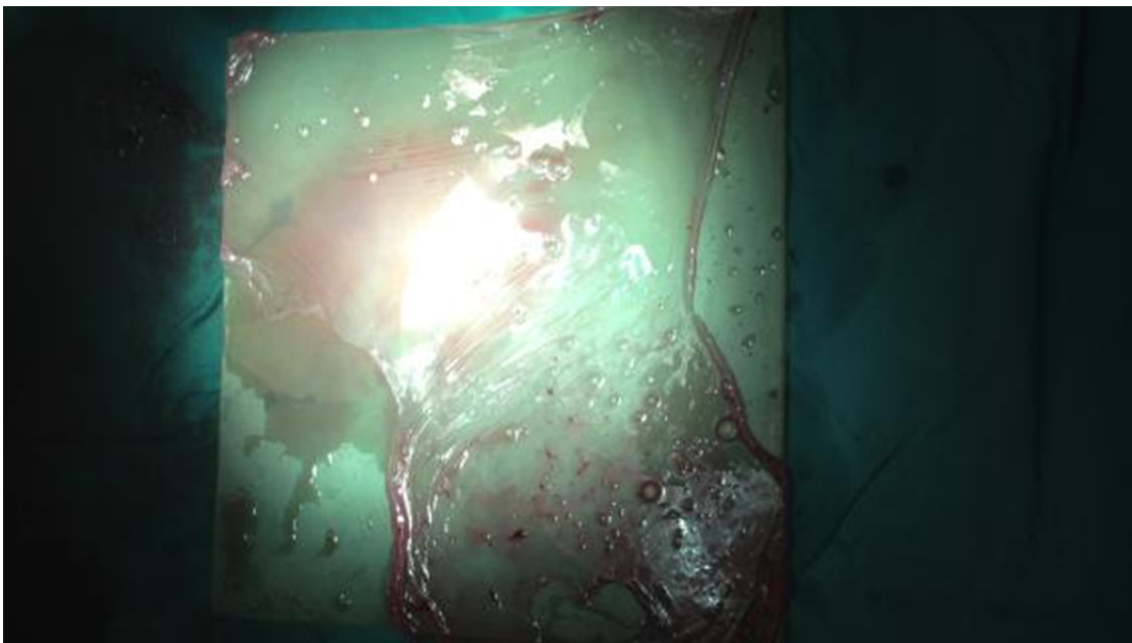


Figure 2: Amniotic layers separated from the chorionic layers before placement in dilute povidone-iodine saline solution.

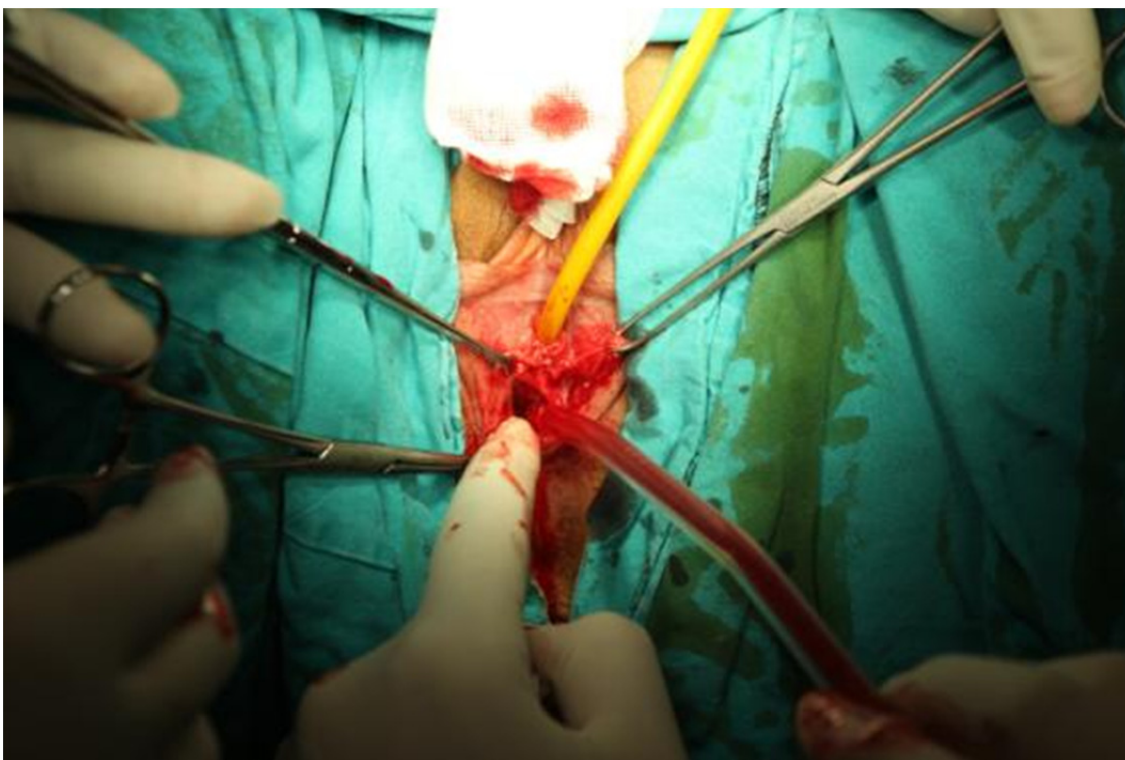


Figure 3. Transverse incision at the perineum traversing the dimple(s).

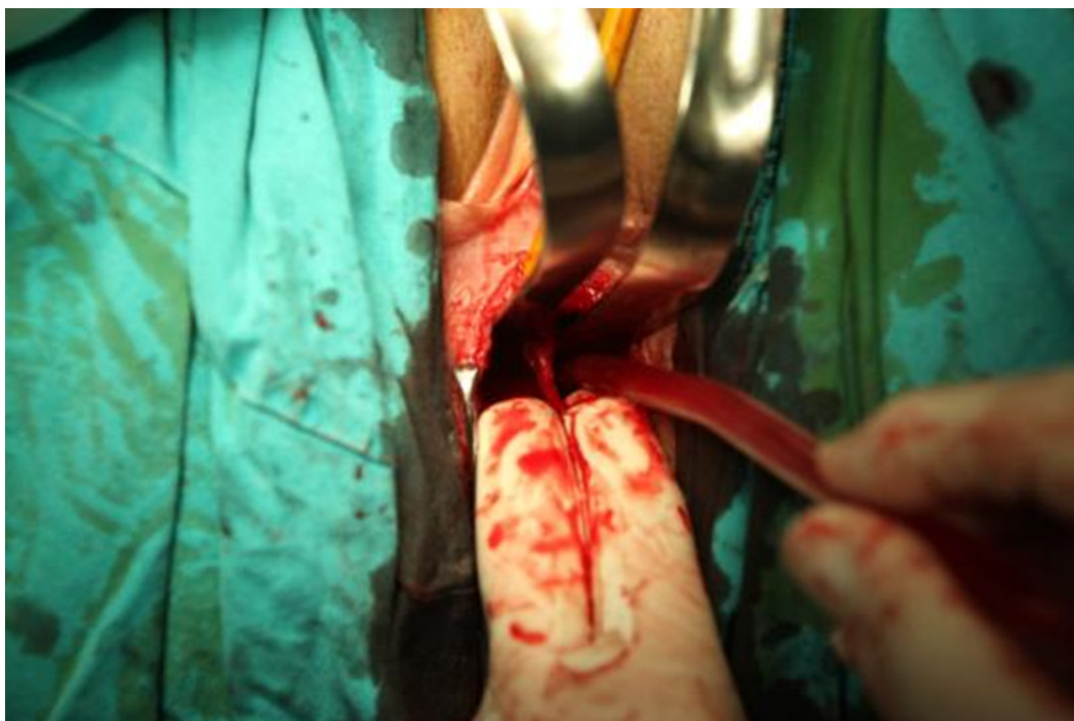


Figure 4. Double tunnels formed with thin septum in between held by fingers, before being incised to form a single vaginal space

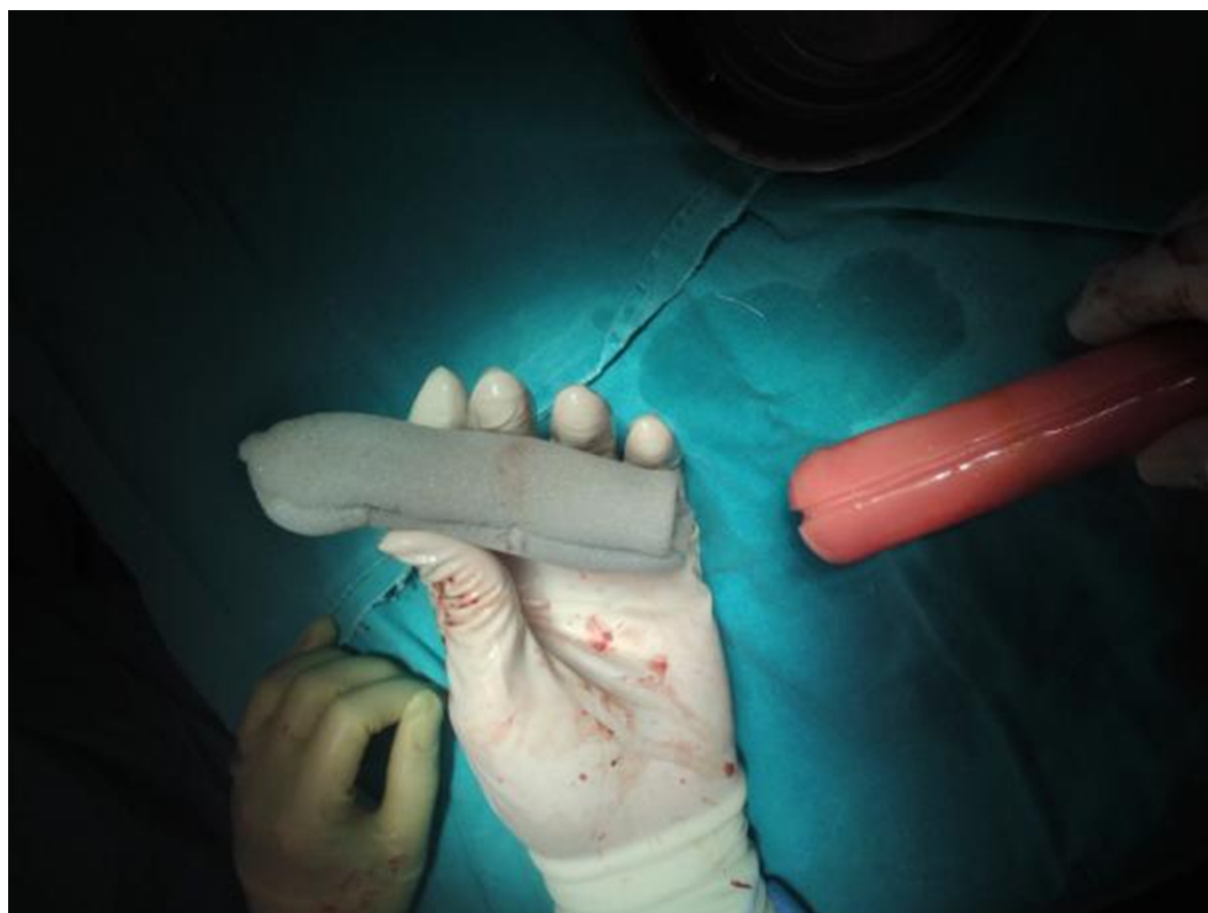

Figure 5. The (polymethyl methacrylate) mould and foam outer sheath to cover

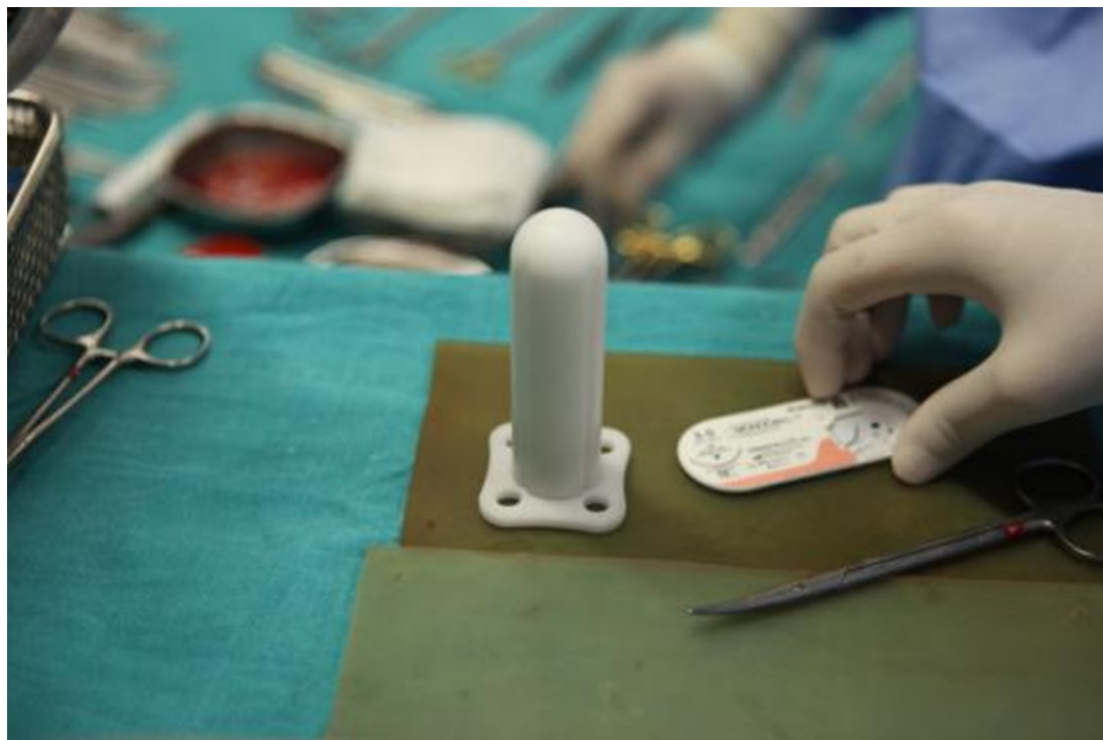

Figure 6. Teflon mould as alternative to dental (polymethyl methacrylate) material

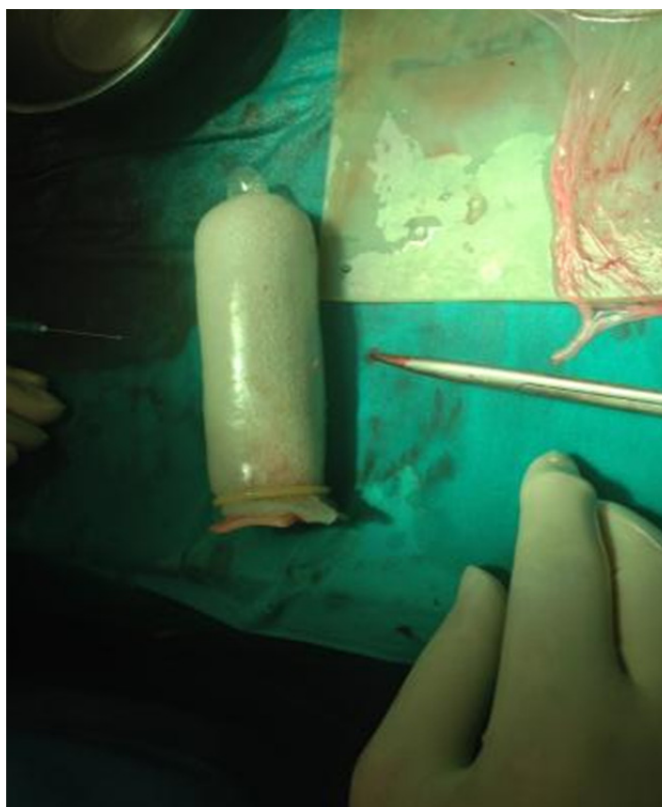


Figure 7. Vaginal mould fully prepared with grooved dental material (polymethyl methacrylate) inner shaper, covered by foam coat and finally by a condom with several pinholes. The amniotic membranes seen aside on silicon plate are ready to be spread over tulle gras, with mesenchymal surface facing up

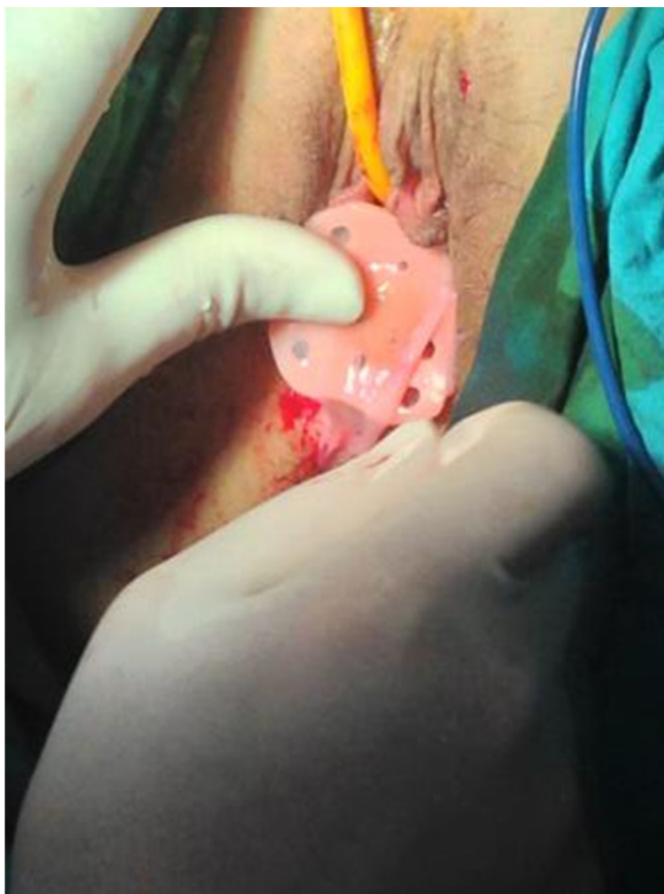

Figure 8. Mould complete with the graft inserted. The holes at the base of the mould are intended first to enable stitching and consequently for threading pediatric serum tubing to use for wrapping around the buttocks and waist when the patient uses the mould at home for six weeks following discharge.

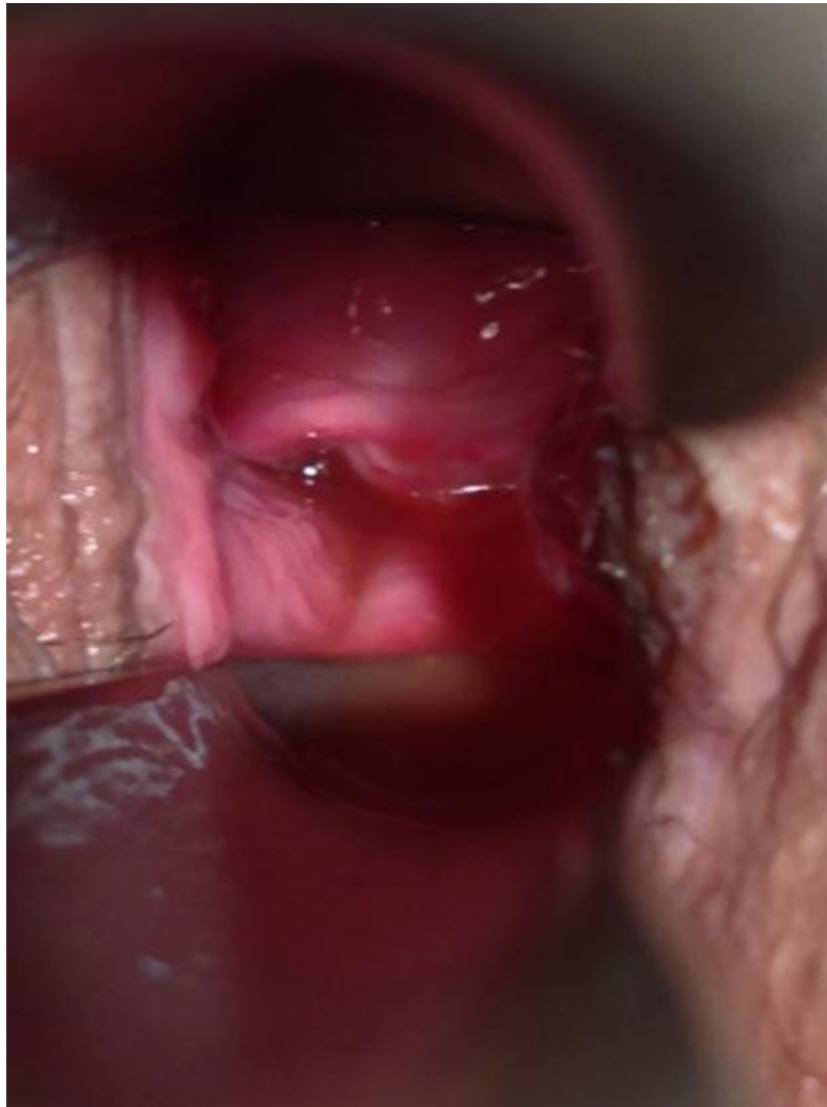

Figure 9. Seven weeks postoperatively, vaginal epithelium looks natural. Depth measures 9 cm.

3. Results

The graft take was satisfactory in all cases and at the clinic on the 7th week postoperatively, epithelialization was found to be in progress by observation (Figure 9). The patients expressed no major complaints throughout the hospital stay and after discharge, when they were asked to use the moulds (the same ones used at the operation) for six weeks at night and during the day as much as possible. Estriol cream was prescribed for use before reinsertion. After that period the patients were advised to wear the mould only at night if there would be no regular intercourse. A follow-up examination at 7th week and after 12 months postoperatively revealed satisfactory anatomic (on examination) and functional result (on interview of the patient, whether intercourse was satisfactory or not). The anatomic results are summarised in Table 2. The patients were further contacted at the time of the preparation of this article. Two of them (9 years and 2 years since the operation, case 2 and case 3 respectively) had abandoned wearing the mould after the first six weeks and had never used it again, but had regular intercourse since (2 – 4 per week). They expressed complete satisfaction and no complaints. They were not seen at the clinic further. One patient who had been operated a year and a half ago (case 1) described her husband's complaint of "laxity". This patient was seen at the outpatients clinic with the spouse and re-examined. The vaginal depth was found to be about 5 centimeters and could be stretched to 7 at most with some blunt pressure before discomfort arised. The couple admitted that they are not having frequent intercourse, on the average 1-2 per week when together but then interrupted by several months of coital inactivity as the husband has to be away for business. The lady admits to having never used the mould even in those periods. The "laxity" was not quite there, two finger

insertion was easy but adequate. Reduced depth was probably the real cause of dissatisfaction. She was advised to apply the mould for three months at least 2 times daily for 30 minutes and at night too, whenever possible, and then come for a review.

Table 2. Anatomic results. All had a vagina of adequate width allowing two fingers

Case/Age	Mold removal time	Vaginal depth 7th weeks	Vaginal depth after 12 months
Patient 1/ 33 years old	10 days	10 cm	6 cm
Patient 2/ 28 years old	7 days	9 cm	10 cm
Patient 3/ 28 years old	7 days	8 cm	7 cm

4. Discussion

There are several other methods of creating a neovagina, all of which have merits as well as disadvantages. These, as well as the allograft technique we applied here (which, as described above, also has many differences from others in details) have been compared and evaluated in the excellent update-review by Callens et al., 2014, where out of the 6700 articles identified (all there is published in English as stated by the authors) 190 were analysed. The authors concluded that on the balance, weighing anatomical success (depending on what length of vaginal depth and girth is taken as “successful” but at least 6 cm depth and two finger allowance), functional success (which can be alternately defined as coitus or satisfaction with sex), complication rates and morbidity against each other, vaginal dilation should be given the first chance, then traction vaginoplasty (Vechietti and modifications) then peritoneal vaginoplasty - Davydov procedure (Davydov & Zhvitiashvili, 1974) and lower down in order, grafting or intestinal procedures. However in our opinion there are downsides to this order of approach : Vaginal dilation is time-consuming and requires extreme patient effort. It is also not free from complications like vaginal prolapse, to name one. The functional success rate extends to no more than 75%. Vechietti procedure necessitates strong analgesia during daily tightening, also requires self dilation and is also not free from complications like rectal or bladder injuries. Davydov procedure is known to have disadvantages like insufficient lubrication, potential bladder and rectum injury, prolapse and need for long - term self dilation. Bowel vaginoplasty has several disadvantages like requirement of a bowel anastomosis, excessive discharge, high complication rate and abdominal scars. Mc Indoe with split-thickness skin graft leaves scarring in the donor site and there is considerable risk of contracture.

Amniotic membrane as allograft in a McIndoe vaginoplasty has the advantages of a short operating time, low complication rate while avoiding abdominal approaches with potential complications, scarring in no part of the body and no necessity of long-term self-dilation. In studies by (Morton & Dewhurst, 1986; Sharma, Dahiya, Chechi, & Sirohiwal, 2008; Bleggi-Torres, Werner, & Piazza, 1997), the anatomical success (depth \geq 8cm easy two finger insertion) rate stands at 88% to 100%. In these three studies consisting of a total of 54 cases, there are three complications: two rectal injuries and one rectovaginal fistula.

The technique we herein describe is based on and in accordance with established plastic surgery principles on skin grafting (Thorne et al., 2007). Most other reports of vaginoplasty utilising amniotic membrane we have been able to study have not described the preparation of the graft in detail. Those who have done so briefly mentioned wrapping the fetal membranes over some bulk of material like condom stuffed with gauze, foam mold covered with a condom (Mhaskar, 2005; Rathod & Samal, 2014) or a mold of glass covered with tulle gras (Fotopoulou, Sehouli, Gehrmann, Schoenborn, & Lichtenegger, 2010) all of which are reported to work anyway. Those techniques and materials briefly described as such have similarities to ours but nevertheless we think the basic plastic surgery principles of grafting as we adhered to in our cases should better be applied for ensuring success. These are secure contact of the graft (amniotic membrane) with the host surface (newly created space) by a sufficiently firm mould with either grooves alongside or perforations into a hollow core to allow drainage, covered with a foam layer to absorb exudate and better comply with irregularities of the host surface, then covered with a condom which is scored (with many perforations all over) to isolate the sticky surface of the foam, then a layer of tulle gras (an old-time standard of skin grafting, also serving here to facilitate the removal of the mould and prevent

unavoidable movements to exert shearing effect on the graft bed) and finally the scored/meshed amniotic membrane. After being neatly separated from the chorionic membrane, amniotic mesenchymal surface must be applied to the raw surface of the dissected vaginal tunnel. It is the mesenchymal surface which has strong adhering properties (first by fibrin deposition then by microangiogenesis as in the natural history of graft “take”). The outcome has been indisputably demonstrated to be a complete epithelialization with cell layers organised as in the normal vaginal epithelium (ie., superficial, intermediate and deep layers) by electron microscopy (Bleggi-Torres, Werner, & Piazza, 1997).

As opposed to using amniotic membrane, split – thickness skin graft has many disadvantages. Scarring to some extent at the donor site basically depends on the thickness of the graft taken. The thinner the split-thickness graft the better for the donor site and initial contracture of the graft (thus the neovagina) but the secondary contracture (shrinking after revascularising at the vaginal space) is more marked and lies at the root of long-term dissatisfaction expressed as dysparunia or shrinkage of the neovagina. A thicker split-thickness skin graft on the other hand does not contract as much as a thin one in the long term but does so more at the immediate post-grafting period (primary contracture) and is less readily “taken” by any host tissue in general. The donor site of a thick split-thickness graft suffers more aesthetically. The amniotic membrane on the other hand, used as in the above described vaginal construction method, with its stem cells embedded in the mesenchymal surface (Tabatabaei et al., 2014) is capable of regenerating the natural layers of the vaginal epithelium (Bleggi-Torres, Werner, & Piazza, 1997) hence despite too small case numbers in too many centres to provide better statistical power and significance this method has at least a theoretical superiority in terms of long-term success and absence of late complications. Although two of our three cases were fully successful anatomically and functionally, one who did not comply with the medium-term (6 weeks to 12 months) postoperative advice presented an unsuccessful outcome. It seems that once normal coitus commences after the first six weeks and maintained regularly, there seems to be actually no need for “maintenance dilation” especially when the two patients who express full satisfaction after 2 and 9 years are considered. Admittedly, the number of cases here presented are far from enough to draw any conclusion but we think the two successful cases are in support of the literature where larger numbers of successful amnion vaginoplasties are reported. Furthermore, it should also be noted that interview of the patients did not include The Female Sexual Function Index (FSFI) which could evaluate the results more reliably and perhaps enable us to handle the patient with a rather unsuccessful result earlier.

The amniotic membrane is readily available, it has very low antigenicity and has antimicrobial properties as well. The time interval between the operation and commencement of sexual activity is relatively short and perhaps even more importantly, predictable. The cultural background of the patients do play a role in achieving anatomical success and obtaining reliable feedback on functional results. These facts may also favour one procedure over another. After considering all aspects ranging from age, preference and cultural background to psychological condition, the exact procedure should be tailored to each patient with vaginal agenesis.

Funding Statement

We certify that we had no relationship with companies that may have a financial interest and we did not receive any financial support.

IRB

Approval of the “Ethics Committee of Sisli Memorial Hospital” has been obtained for the operations subject to the study.

Consent

Written consents have been obtained from all three operated patients and spouses. Verbal consent only have been obtained from the patients who donated the amniotic membranes after their Cesarean delivery.

Competing Interests Statement

The authors declare that there is no conflict of interests regarding the publication of this paper.

References

- Bleggi-Torres, L. F., Werner, B., & Piazza, M. J. (1997). Ultrastructural study of the neovagina following the utilization of human amniotic membrane for treatment of congenital absence of the vagina. *Braz J Med Biol Res*, 30(7), 861-864. <http://dx.doi.org/10.1590/S0100-879X1997000700007>

- Brindeau A. (1934). Création d'un artificiel à l'aide des membranes ovulaires d'un oeuf à terme. *Gynecol Obstet (Paris)*, 29, 385.
- Callens, N., De Cuyper, G., De Sutter, P., Monstrey, S., Weyers, S., Hoebeke, P., & Cools, M. (2014). An update on surgical and non-surgical treatments for vaginal hypoplasia. *Human Reproduction Update*, 20(5), 775-801. <http://dx.doi.org/10.1093/humupd/dmu024>
- Chakrabarty, S., Mukhopadhyay, P., & Mukherjee, G. (2011). Sheares' method of vaginoplasty - our experience. *J Cutan Aesthet Surg*, 4(2), 118-121. <http://dx.doi.org/10.4103/0974-2077.85032>
- Committee on Microbiological Safety of Blood and Tissues for Transplantation. (1996). *Guidance on the microbiological safety of human tissues and organs used in transplantation*. Department of Health, London, England.
- Davydov, S. N., & Zhvitiashvili, O. D. (1974). Formation of vagina (colpopoiesis) from peritoneum of Douglas pouch. *Acta Chir Plast*, 16, 35-41.
- Fotopoulou, C., Sehoul, J., Gehrman, N., Schoenborn, I., & Lichtenegger, W. (2010). Functional and anatomic results of amnion vaginoplasty in young women with Mayer-Rokitansky-Küster-Hauser syndrome. *Fertil Steril*, 94(1), 317-323. <http://dx.doi.org/10.1016/j.fertnstert.2009.01.154>
- Mhaskar, R. (2005). Amniotic membrane for cervical reconstruction. *Int J Gynaecol Obstet*, 90(2), 123-127. <http://dx.doi.org/10.1016/j.ijgo.2005.04.015>
- Morton, K. E., & Dewhurst, C. J. (1986). Human amnion in the treatment of vaginal malformations. *Br J Obstet Gynaecol*, 93, 50-54. <http://dx.doi.org/10.1111/j.1471-0528.1986.tb07813.x>
- Raga, F., Bauset, C., Remohi, J., Bonilla-Musoles, F., Simon, C., & Pellicer, A. (1997). Reproductive impact of congenital Mullerian anomalies. *Hum Reprod*, 12(10), 2277-2281. <http://dx.doi.org/10.1093/humrep/12.10.2277>
- Rathod, S., & Samal, S. K. (2014). Secondary vaginal atresia treated with vaginoplasty using amnion graft: A case report. *J Clin Diagn Res*, 8(11), 5-6. <http://dx.doi.org/10.7860/JCDR/2014/10674.5207>
- Sharma, D., Dahiya, K., Chechi, K., & Sirohiwal, S. (2008). Vaginoplasty with amnion grafting: An experience. *Journal of Gynecologic Surgery*, 24(2), 61-66. <http://dx.doi.org/10.1089/gyn.2008.B-02296-2>
- Tabatabaei, M., Mosaffa, N., Nikoo, S., Bozorgmehr, M., Ghods, R., Kazemnejad, S., ... Zarnani, A. H. (2014). Isolation and partial characterization of human amniotic epithelial cells: the effect of trypsin. *Avicenna J Med Biotechnol*, 6(1), 10-20.
- Thorne, C. H. (2007). Techniques and Principles in Plastic Surgery. In C. H. Thorne, R. W. Beasley, S. J. Aston, S. P. Bartlett, G. C. Gurtner, & S. L. Spear (Eds.), *Grabb and Smith's Plastic Surgery* (6th Ed), (pp. 3-14). Philadelphia: Wolters Kluwer Health/Lippincott Williams & Wilkins.

Copyrights

Copyright for this article is retained by the author(s), with first publication rights granted to the journal.

This is an open-access article distributed under the terms and conditions of the Creative Commons Attribution license (<http://creativecommons.org/licenses/by/4.0/>).