

Caries of Elbow: An Infrequent Location with Diagnostic Quandary: A Case Report

Tarun Kumar^{1*}, Lucky Verma², Bhanu Awasthi², Jasbir Singh² and Sajid Khan²

¹Reginal Hospital Bilaspur, Himachal Pradesh, 174001, India.

²Dr. Rajendra Prasad Govt. Medical College, Tanda Kangra, HP, India.

Authors' contributions

This work was carried out in collaboration among all authors. Author TK designed the study, performed the statistical analysis, wrote the protocol and wrote the first draft of the manuscript. Authors LV, BA, JS and SK managed the analyses of the study. Author BA managed the literature searches. All authors read and approved the final manuscript.

Article Information

Editor(s):

- (1) Dr. Ikem, Innocent Chiedu, Obafemi Awolowo University, Nigeria.
- (2) Dr. Parth Trivedi, C.M. Patel College of Physiotherapy, India.

Reviewers:

- (1) Dushantha Madegedara, National Hospital, Sri Lanka.
- (2) K. Venkatachalam, Chettinad University, India.

- (3) Vivek Bhambhu, P. D. Hinduja Hospital and MRC, India.

Complete Peer review History: <http://www.sdiarticle4.com/review-history/57962>

Case Report

Received 01 April 2020

Accepted 07 June 2020

Published 08 June 2020

ABSTRACT

Tuberculous disease of elbow is a very rare entity and constitutes approximately 2-5% of all cases of skeletal tuberculosis and accounts for 10% of all extra-pulmonary tuberculosis. The disease starts from lower end humerus, olecranon region or from upper end of radius. We report a case of extra pulmonary Tuberculosis involving left elbow joint. Early diagnosis and intervention is very necessary to prevent serious joint and bone destruction. Although biopsy is required to make definitive diagnosis, it is imperative that Orthopedician understand the typical clinical presentation and radiological imaging. Reviews of literature with emphasis on clinical manifestations, laboratory findings and imaging features are studied.

Keywords: Tuberculosis; CBNAAT; adenosine deaminase; MRI; AFB.

*Corresponding author: Email: dr.tarunkumar86@gmail.com;

1. INTRODUCTION

Musculoskeletal tuberculosis has been increasing in incidence in the past few years due to the emergence of drug resistant mycobacterium [1]. Musculoskeletal system is affected in 1-3% of patients with tuberculosis and accounts for 10% of all extra-pulmonary tuberculosis with the most frequently affected bones are vertebrae (51%), pelvis (12%), hip and thigh (10%), knee and leg (10%), and ribs (7%). Tubercular infection of the upper limbs is infrequent with elbow joint most frequently affected accounting for 2 to 5% of all skeletal localizations [1,2]. The family history of tuberculosis is present in only 50 percent cases. A negative Mantoux test does not rule out tuberculosis and clinical and radiologic features of tuberculous disease of joints may mimic those of many other diseases thus hampering the decision making. Early diagnosis of the disease is very important because delayed treatment is associated with severe morbidity. Thus proper clinical, laboratory and radiological assessment of patients with musculoskeletal tuberculosis is often key to adequate diagnosis and early treatment.

2. MATERIALS AND METHODS

2.1 Case Report

A 25 year old female patient presented with left elbow joint pain and swelling for 2 months with history of intake of non steroidal anti inflammatory drugs from local hospitals with poor response to treatment. On clinical examination there was minimal swelling in the elbow joint (anconeus triangle), painful passive range of motion with mild tenderness over lateral epicondyle (Fig. 1). There was no history of tuberculosis or contact with tuberculosis,

diabetes and hypertension. The hematological investigations showed elevated total leucocyte count ($13.0 \times 10^9/L$), lymphocytosis and elevated erythrocyte sedimentation rate (80mm in first hour) and rheumatoid factor was negative. Plain Radiograph of both the elbow was taken for comparison. Left elbow joint showing reduced Joint space, Subarticular Osteopenia, Articular erosions (Pheemister Triad) (Fig. 4). Suspicious of tuberculosis was made and contrast enhanced MRI was done which reported synovial enhancement, articular erosions, subarticular osteopenia and joint effusions (Fig. 3). Further joint aspiration was done in minor operation theatre and straw colored fluid was aspirated and was sent for AFB staining, CBNAAT testing, Adenosine Deaminase levels, AFB, Fungal culture and sensitivity testing. The CBNAAT (Cartridge Based Nucleic Acid Amplification Test) and AFB staining was negative which remained quandary but Adenosine Deaminase levels were significantly raised (200 IU/L). The joint aspirate fluid was also sent of AFB culture and sensitivity which showed the growth of mycobacterium after 45 days of inoculation. The bacterium was sensitive to all first line antitubercular drugs. The fungal culture of the fluid was negative. The case was discussed with our worthy senior resident and consultant and patient was put on antitubercular treatment as per the Index- TB guidelines by government of India for extra pulmonary skeletal tuberculosis for recommended duration of 18 months (category 1). The patient was followed up regularly every month and after 8 months of follow up patient showed marked improvement in symptoms and range of motion at elbow (Fig. 2) and there was also improvement in radiological features (Fig. 5). The patient is still on antitubercular treatment for recommended duration for 18 months as per Index-TB guidelines by the government of India.

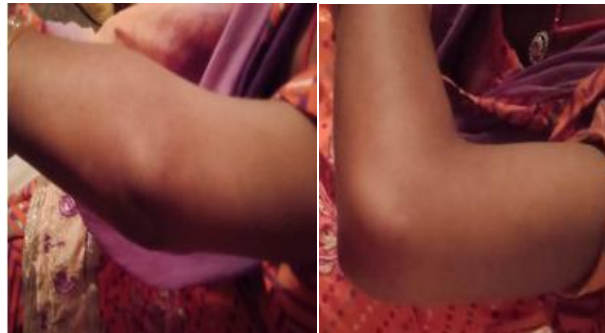

Fig. 1. Clinical photographs at the initiation of antitubercular treatment showing decreased range of motion from 70 to 90 degree

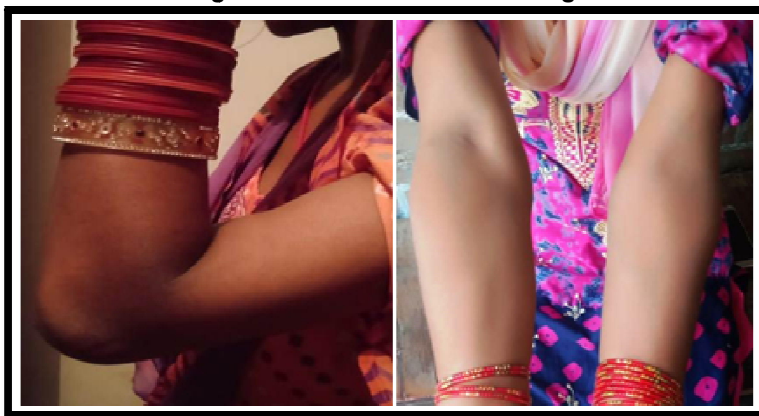

Fig. 2. Images showing improved range of 30 to 100 degree at 8 months of antitubercular treatment

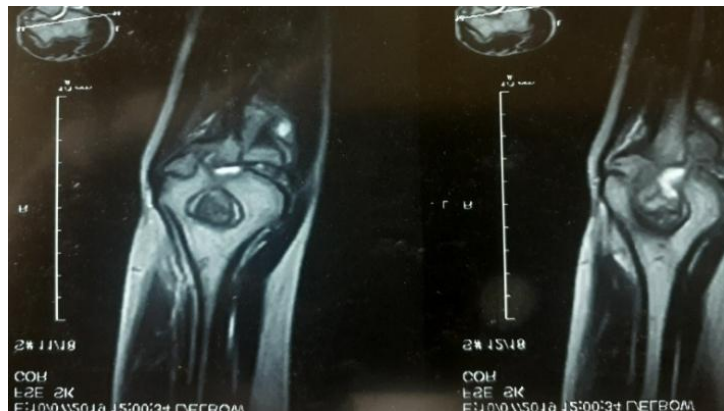

Fig. 3. Initial MRI of left elbow showing synovial enhancement, articular erosions, subarticular osteopenia and joint effusion

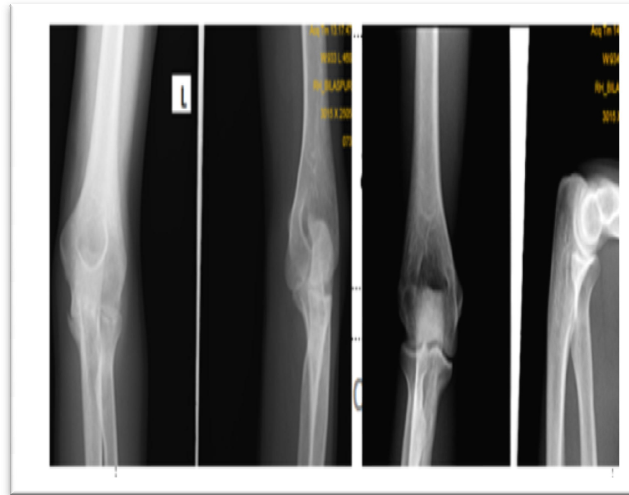


Fig. 4. Comparative views of X ray of marked left (Affected) and right (unmarked), showing reduced Joint space, subarticular osteopenia, articular erosions (Pfeister triad). Other joint space in normal condition

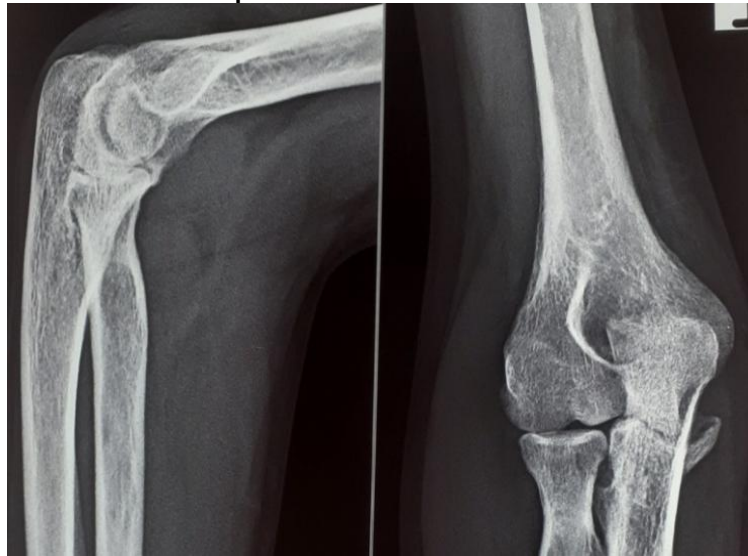

Fig. 5. 8 months follow up X ray of affected elbow of the patient with improved bony lesions

3. DISCUSSION

Musculoskeletal tuberculosis accounts for 1-3% of total mycobacterial infections. Tubercular arthritis of elbow joint accounts for 2-5% of musculoskeletal tubercular manifestation. As in other infectious arthritis, tubercular arthritis is usually monoarticular but in 10% cases it may be polyarticular. Musculoskeletal involvement is caused by either dissemination of distant foci by blood, lymph or direct spread of tubercle bacilli from surrounding body structures [3,4].

Symptoms of tubercular arthritis are obtrusive, which are clinically manifested as local swelling and chronic pain of a single joint with diurnal variations (night cries) accompanied by progressive loss of range of motion. Swelling of joint and pain which is increased by activity, are the most common manifestation [5,6]. Because of slow progression of disease and the obtrusive symptoms, diagnostic investigations are often not advised until the disease has advanced.

In the early stage, tubercular arthritis of elbow may be easily be confused with trauma, rheumatoid arthritis, septic arthritis and lateral epicondylitis. A significant delay has been observed between the onset of symptoms and the definitive diagnosis which commonly ranges from 5-47 months [7,8]. Systemic symptoms may include evening rise of temperature, easy fatigability, generalised body aches decreased appetite, decreased weight, night cries, tachycardia and anemia, but these symptoms are very rare.

In the present case, the patient complained of the pain present in the left elbow joint for last 2 months. Under the impression of lateral epicondylitis, the treatment was initiated; however, the patient had poor response to the treatment and then underwent additional laboratory tests. These laboratory parameters such as total leucocyte count, ESR and CRP were elevated. On admission, the patient underwent an aspiration of the synovial fluid and an imaging study. Approximately 8 cc of synovial fluid, straw colored, thick in consistency was aspirated and sent for Cartridge Based Nucleic Acid Amplification Test, Adenosine deaminase levels, routine microscopy, AFB, fungal culture and sensitivity testing. The Cartridge Based Nucleic Acid Amplification Test and AFB staining was negative but Adenosine Deaminase levels were significantly raised (200 IU/L) and there was lymphocytosis in microscopy. The AFB culture was positive and sensitive to all first line antitubercular drugs. The fungal culture was negative. On contrast MRI there was synovial enhancement, articular erosions, subarticular osteopenia and joint effusion. Considering all these evidences patient was put on antitubercular treatment as per Index-TB guidelines for skeletal tuberculosis by government of India for 18 months (Category1). The patient was regularly followed every month for 8 months. The range of motion was allowed at elbow. Patient showed good response with decrease in pain at elbow after 8 months of elbow and improved range of motion. And there was gross improvement in radiology of the affected joint after 8 months of follow up.

The Xray findings of tubercular arthritis are very uncertain in the early stage. After several months following the onset of symptoms, there may be presence of periarticular osteopenia and soft tissue swelling. On advancement of the disease, the bone erosions and joint space

narrowing may be seen on X ray [9,10,11]. Contrast MRI scans are more specific as they can clearly visualize such findings as soft tissue swelling, joint effusion, joint erosions and synovial enhancement [5,9,12,13].

A gold standard for the diagnosis of tubercular arthritis is to microscopically identify *M. tuberculosis*. On AFB staining of the synovial fluid, positive findings are observed in only 20-25% of samples. A culture test of the synovial fluid can identify *M. tuberculosis* in 60-80% of samples. A tissue biopsy of synovial membrane is more specific for diagnosis. However, if *M. tuberculosis* was not identified, anti-tuberculosis treatment can be started in cases in which there are granulomatous inflammatory findings [5]. Also, in the current case, a diagnosis of tubercular arthritis was made based on X ray , MRI findings and biochemical analysis of synovial aspirate which depicted elevated Adenosine Deaminase levels

4. CONCLUSION

Skeletal Tuberculosis has very low incidence and tuberculosis of upper limb is a rare entity. The patients presenting with chronic pain in elbow region especially lateral epicondyle region may be misdiagnosed as lateral epicondylitis as mentioned herein. The bacilli detection rate of AFB staining, CBNAAT and even AFB culture in synovial fluid is also not up to hundred percent. In every patient, the surgeon cannot go for synovial biopsy because of wound dehiscence and chronic sinuses. So, the diagnosis of articular tuberculosis in endemic country likes India is empiric based of clinical examination, radiological investigations like contrast MRI and minimal invasive investigations like synovial fluid examination. The empiric antitubercular treatment may be started as per the guidelines of national programme for extra pulmonary skeletal tuberculosis for recommended duration.

CONSENT

As per international standard informed and written participant consent has been collected and preserved by the authors.

ETHICAL APPROVAL

As per international standard written ethical permission has been collected and preserved by the author(s).

COMPETING INTERESTS

Authors have declared that no competing interests exist.

REFERENCES

1. Rahman MS, Brar R, Konchwalla A, Sala MJ. Pain in the elbow: A rare presentation of skeletal tuberculosis. *J Shoulder Elbow Surg.* 2008;17(1):e19–e21.
2. Akqun U, Erol B, Cimsit C, Karahan M. Tuberculosis of the knee joint: A case report. *Acta Orthop Traumatol Turc.* 2008;42:214–218.
3. Domingo A, Nomdedeu M, Tomas X, Garcia S. Elbow tuberculosis: An unusual location and diagnostic problem. *Arch Orthop Trauma Surg.* 2005;125:56–58.
4. Chen WS, Wang CJ, Eng HL. Tuberculous arthritis of the elbow. *Int Orthop.* 1997;21:367–370.
5. Erden H, Baylan O, Simsek I, Dinc A, Pay S, Kocaoglu M. Delayed diagnosis of tuberculous arthritis. *Jpn J Infect Dis.* 2005;58:373–375.
6. Giehl JP, Kluba T, Lebherz C. The course of inflammatory mediators after elective orthopedic interventions. *Z Orthop Ihre Grenzgeb.* 2000;138:181–184.
7. Chang DJ, Yoon DM, Kang YS, Yoon KB. Chronic back pain proven to be spinal tuberculosis. *Korean J Pain.* 2008;21:74–79.
8. Hunfeld KP, Rittmeister M, Wichelhaus TA, Brade V, Enzensberger R. Two cases of chronic arthritis of the forearm due to *Mycobacterium tuberculosis*. *Eur J Clin Microbiol Infect Dis.* 1998;17:344–348.
9. Larsson S, Thelander U, Friberg S. C-reactive protein (CRP) levels after elective orthopaedic surgery. *Clin Orthop Relat Res.* 1992;275:237–242.
10. Mohana-Borges AV, Chung CB, Resnick D. Monoarticular arthritis. *Radiol Clin North Am.* 2004;42:135–149.
11. Asaka T, Takizawa Y, Kariya T, Nitta E, Yasuda T, Fujita M, et al. Tuberculous Tenosynovitis in the Elbow Joint. *Intern Med.* 1996;35:162–165.
12. Scott DL, Steer S. The course of established rheumatoid arthritis. *Best Pract Res Clin Rheumatol.* 2007;21:943–967.
13. Mathews CJ, Coakley G. Septic arthritis: Current diagnostic and therapeutic algorithm. *Curr Opin Rheumatol.* 2008;20:457–462.

© 2020 Kumar et al.; This is an Open Access article distributed under the terms of the Creative Commons Attribution License (<http://creativecommons.org/licenses/by/4.0>), which permits unrestricted use, distribution, and reproduction in any medium, provided the original work is properly cited.

Peer-review history:

The peer review history for this paper can be accessed here:
<http://www.sdiarticle4.com/review-history/57962>