



FNAC of Different Breast Lesions in Subset of Rural Areas of Sindh

**Santosh Kumar Sidhwani^{1*}, Paras Mahesh², Haresh Chand³,
Haider Abbas Mandviwala⁴, Zahra Saifuddin Rajbhoy⁴
and Jabbar Ahmed Qureshi⁵**

¹Department of Pathology, Ziauddin University, Karachi, Pakistan.

²Shaheed Mohtarma Benazir Bhutto Medical College Lyari, Pakistan.

³Department of Pathology, Gambat Medical College, Gambat, Pakistan.

⁴Ziauddin University, Karachi, Pakistan.

⁵Department of Pharmacology, Ziauddin University, Karachi, Pakistan.

Authors' contributions

This work was carried out in collaboration among all authors. Authors SKS and HC designed the study, performed the statistical analysis, wrote the protocol and wrote the first draft of the manuscript.

Authors PM and JAQ managed the analyses of the study. Authors HAM and ZSR managed the literature searches. All authors read and approved the final manuscript.

Article Information

DOI: 10.9734/JAMMR/2020/v32i430394

Editor(s):

(1) Dr. Thomas I. Nathaniel, University of South Carolina, USA.

Reviewers:

(1) Shigeki Matsubara, Jichi Medical University, Japan.

(2) Deepak Sethi, Rabindra Nath Tagore Medical College, Udaipur, India.

Complete Peer review History: <http://www.sdiarticle4.com/review-history/55192>

Original Research Article

Received 28 December 2019

Accepted 02 March 2020

Published 26 March 2020

ABSTRACT

Background: In the 1970's the introduction of Fine Need Aspiration Cytology (FNAC) proved to be the key method for examining the nature and malignant potential of many palpable lesions like thyroid, salivary glands and lymphadenopathies. Breast pathologies is one of the entity that can also be diagnosed with FNAC. Breast cancer is the most common malignancy of women with overall 100,000 cases being reported annually around the globe. The most frequent lesion encountered using FNAC in breast is fibro-adenoma followed by fibrocystic disease, breast abscess, chronic inflammatory conditions and suspicious malignant masses. In current cross sectional study we tried to find frequency of different breast lesions by FNAC.

Methodology and Results: 649 samples were recruited from the Vital Laboratory Larkana with different pathological lesions of breast during the year 2014 and 2015 by non-probability

*Corresponding author: E-mail: Santosh.kumar@zu.edu.pk;

consecutive sampling. 613 (95%) were females and 32 (5%) were male with mean age of 30.8 ± 12.8 years. Majority of case were of 20-39 years of age (55.8%). Most of the cases were diagnosed with benign lesions (329, 51%) followed by inflammatory lesions (132, 20.5%) and gynecomastia (15, 2.3%). Right breast was more affected (329, 51%). In present study we found a strong association of diagnosis with gender ($p = 0.000$) and age ($p = 0.000$).

Conclusion: So in this study it is concluded that large number of females with breast pathologies present with benign lesions like fibro-adenoma at the age of 20-39 years. It is also concluded that in this age group mastitis and abscesses are common due to different risk factors.

Keywords: FNAC; breast lesions; fibrocystic diseases; aspiration; cytology.

1. INTRODUCTION

FNAC is a diagnostic approach, which helps the clinicians in diagnosis of the various lesions [1-3]. Breast pathologies is one of the entity that can also be diagnosed with FNAC [3]. In women, the most common malignant tumor is breast carcinoma with overall 100,000 cases being registered worldwide annually [4]. The most common diagnosis using FNAC in the case of the breast is fibro-adenoma followed by fibrocystic disease, breast abscess, chronic inflammatory conditions and suspicious malignant masses [3]. 90-98% of sensitivity is achieved by using FNAC in clinically palpable breast lesions which gives a definitive diagnosis in 95% cases [5,6].

Pakistan has the highest incidence of breast cancer in Asia, which is 2.5 times higher than India [7]. Prevalence of breast cancer in Pakistan is 56.7-72.9 per 100000 while in India it is less than 28.8 per 100000 [8]. Breast cancers in Pakistani women account for 41% cancers whereas in the list of overall cancers it comprises of 23% of all cancers [9]. Pakistan is a developing country with limited resources FNAC is endorsed as it is comparatively less expensive, rapid and easy to perform [3].

FNAC is performed using a small-gauge needle which has an airtight syringe, and a sample of cellular material is obtained [10]. It is not only used for diagnosis of breast pathologies but can also be used for other lesions like thyroid and lymphadenopathies [10]. FNAC is an inexpensive, uncomplicated and rapid method that does not subject the patient to trauma [3]. It is less painful and gives a quick diagnosis [5]. The percentage of true positives is more than false positives in FNAC [10]. There is no need for anesthesia and therefore it is established as a patient-friendly procedure [10]. That's why it is the early and quick procedure to take the tissue and aspirates for histological analysis of different

common pathologies. In current cross sectional study we tried to find frequency of different breast lesions by FNAC.

2. MATERIALS AND METHODS

645 samples were included in the study with different pathological lesions of breast referred from various medical facilities of territory received at the Vital Laboratory Larkana Sindh during the year 2014 and 2015. Non-probability consecutive sampling was used, then detailed history including different pathological variables were taken followed by physical examination. FNAC was performed on all cases and slides were prepared. Slides were evaluated by a panel of histo-pathologists and the results were recorded. The parameters included in the study were: Sex, age, site of lesion and diagnosis. The lesions were categorized into the inflammatory lesions, abscess, benign, malignant lesions and gynecomastia. Data was analyzed using IBM SPSS version 22. Quantitative data was represented as mean, range, median and standard deviation while qualitative data was represented as frequency and percentage. To find the association between the variables Chi square test was applied and P value < 0.05 was taken as significant.

3. RESULTS

We were able to perform FNAC on 645 patients who presented with different breast lesions. Out of these, 613 (95%) were females and 32 (5%) were males with a ratio of 19:1. The age ranged from 1-80 years with the mean of 30.8 ± 12.8 years, were divided into three groups. 360 cases were found to be 20-39 years (55.8%) followed by 166 patients who fell in the age group of more than 40 years (as shown in Fig. 1). A large number of patients were diagnosed with benign lesions with a frequency of 329 cases (51%) while inflammatory lesions were the 2nd most common diagnosis with a frequency of 132 cases (20.5%) and gynecomastia had the lowest

frequency of 15 (2.3%) (as shown in Fig. 2). Most of the lesions were present on the right breast accounting for 329(51%) of the cases, while the lesions found on the left breast and bilateral breast involvements were 307(47.6%) and 9(1.4%) respectively (as shown in Fig. 3). In present study we found a strong association of diagnosis with gender ($p = 0.000$) and age ($p = 0.000$) (as shown in Tables 1 and 2).

4. DISCUSSION

The need for open surgical biopsy is reduced with use of FNAC [3,5]. It is considered as an

appropriate procedure in debilitated patients as it can be repeated and can be done on multiple lesions [11]. The most common organs on which FNAC is performed are lesions that are easily palpable; these include thyroid, breast, salivary glands and superficial lymph nodes [11].

We enrolled different patients with different breast lesions and we found that out of 645 samples 51% (329) had benign lesions. Out of those, benign lesions fibroadenoma accounted for 281 cases (43.6%) and hyperplastic changes accounted for 17 cases (2.3%) and others.

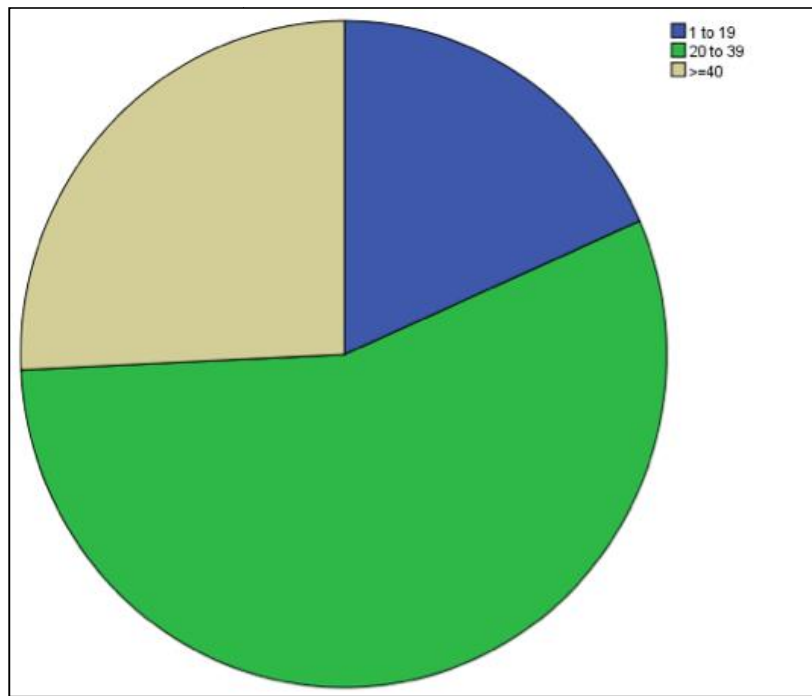


Fig. 1. Frequency of age groups

Table 1. Association of diagnosis with gender

Diagnosis		Gender		Total	P value
		Female	Male		
Inflammatory Lesion	Count	125	7	132	
	% within Diagnosis	94.70%	5.30%	100.00%	
Abscess	Count	86	4	90	
	% within Diagnosis	95.60%	4.40%	100.00%	
Malignancy	Count	76	3	79	0.000*
	% within Diagnosis	96.20%	3.80%	100.00%	
Gynecomastia	Count	0	15	15	
	% within Diagnosis	0.00%	10.00%	100.00%	
Benign Lesions	Count	326	3	329	
	% within Diagnosis	99.10%	0.90%	100.00%	

*=chi square test

Table 2. Association of diagnosis with age

Diagnosis		Age			Total	P value
		1 to 19	20 to 39	= >40		
Inflammatory Lesion	Count	11	94	27	132	
	% within Diagnosis	8.30%	71.20%	20.500%	100.00%	
Abscess	Count	10	63	17	90	
	% within Diagnosis	11.10%	70.00%	18.90%	100.00%	
Malignancy	Count	0	20	59	79	0.000*
	% within Diagnosis	0.00%	25.30%	74.7%	100.00%	
Gynecomastia	Count	3	6	6	15	
	% within Diagnosis	20.00%	40.00%	40.00%	100.00%	
Benign Lesions	Count	95	177	57	329	
	% within Diagnosis	28.90%	53.80%	17.30%	100.00%	

*= chi square test

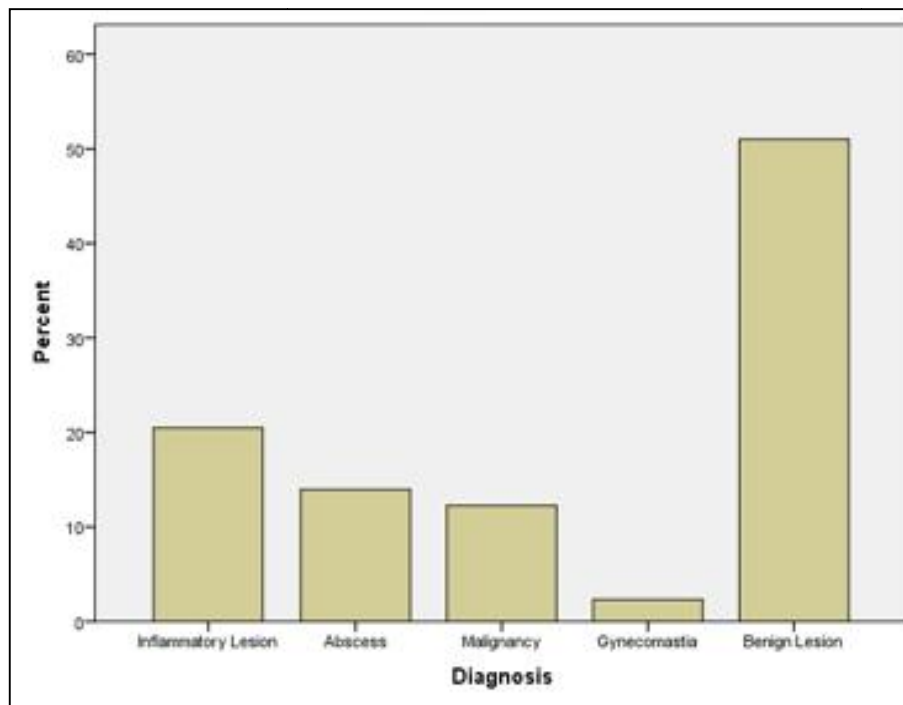


Fig. 2. Frequency of different lesions

These results are in line with the previous studies done by several authors [12-14]. Inflammatory lesions/abscess were the 2nd most frequent breast pathology encountered in present study with a total of 132 cases (20.4%). Our results match with the study done by several authors [12-14].

We found only 15 cases (2.3%) of gynecomastia. In studies conducted by Devi, et al. [14] and Gupta, et al. [15], gynecomastia added up to 78 cases out of 700 (11.4%) and 10 cases out of 161 (5.7%) respectively. The probable reason for the irregularity in results may be due to less

number of male cases (32/5%) reported by several authors [4,16,15]. In present study males cases amounted to 32(5%). The younger generation is embarrassed as they don't admire having a feminine characteristic while the older men are concerned that the breast lesion may be malignant [17]. This can be also explained as males feel shy and uncomfortable in presenting with complaints of gynecomastia [17].

Over the last few decades, the age of developing breast lesions has undergone a significant shift [4]. The most common age group with different breast lesions is from 20-39 years

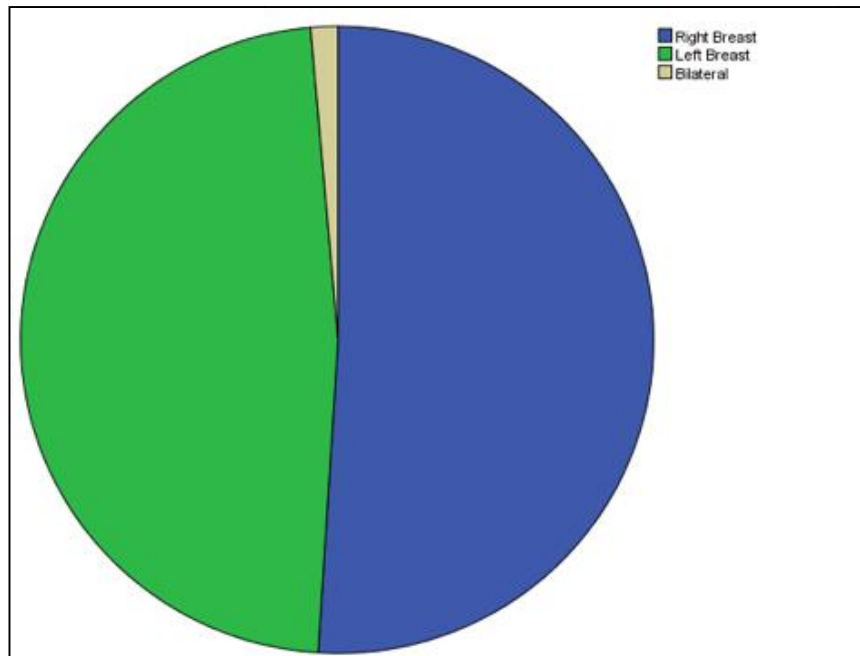


Fig. 3. Frequency of site of lesions

Singh, et al. [18] and Devi, et al. [14] also found the maximum cases in the same age range. The reasons for developing breast lesions at an earlier age are genetic factors, the use of oral contraceptives pills and in Pakistan; a high rate of consanguineous marriages [7].

Although we only found significant association of diagnosis with age and gender however, we didn't follow the cases for further confirmation with biopsies. Most of the patients presented on outpatient basis, thus we couldn't focus on further detailed history and clinico-pathological characteristics. However, a large follow-up study maybe needed to include more parameters.

5. CONCLUSION

So in this study it is concluded that large number of females with breast pathologies present with benign lesions like fibro-adenoma at the age of 20-39 years. It is also concluded that in this age group mastitis and abscesses are common due to different risk factors.

CONSENT

As per international standard or university standard written patient consent has been collected and preserved by the author(s).

ETHICAL APPROVAL

As per international standard or university standard written ethical approval has been collected and preserved by the author(s).

COMPETING INTERESTS

Authors have declared that no competing interests exist.

REFERENCES

1. Singh K, Sharma S, Dubey V, Sharma P. Role of FNAC in diagnosis of breast lumps. *Studies*. 2001;3:8.
2. Zagorianakou P, Fiaccavento S, Zagorianakou N, Makrydimas G, Stefanou D, Agnantis N. FNAC: Its role, limitations and perspective in the preoperative diagnosis of breast cancer. *European Journal of Gynaecological Oncology*. 2005; 26(2):143-9.
3. Rehan M, Qaiser M, Ijaz A. Fine needle aspiration cytology - A pre-operative diagnostic modality in breast lump - A review of 287 cases in a Tertiary Care Hospital. *Journal of Rawalpindi Medical College*. 2019;23(1):12-7.
4. Saha A, Mukhopadhyay M, Das C, Sarkar K, Saha AK, Sarkar DK. FNAC versus core

- needle biopsy: A comparative study in evaluation of palpable breast lump. Journal of Clinical and Diagnostic Research: JCDR. 2016;10(2):EC05.
5. Kazi M, Parshad R, Seenu V, Mathur S, Hareesh K. Fine-Needle Aspiration Cytology (FNAC) in breast cancer: A reappraisal based on retrospective review of 698 cases. World Journal of Surgery. 2017;41(6):1528-33.
 6. Jan Y, Hussain S, Waqas MS, Din A, Khan A. Comparison of Fine Needle Aspiration Cytology (FNAC) and trucut biopsy in evaluation of suspicious palpable breast lesions. Rawal Medical Journal. 2016;41(2):205-8.
 7. Hanif M, Sabeen B, Maqbool A, Ahmed A, Nadeem F, Habib S. Breast cancer: Incidence (Thirteen year data analysis) and one year clinicopathological data of patients in a tertiary care cancer hospital. Int J Biol Biotech. 2015;12(3):373-9.
 8. Shaukat U, Ismail M, Mehmood N. Epidemiology, major risk factors and genetic predisposition for breast cancer in the Pakistani population. Asian Pacific Journal of Cancer Prevention. 2013;14(10):5625-9.
 9. Fayyaz MB, Niazi IK. Diagnostic accuracy of us-fnac of axillary lymph nodes in patients with primary breast cancer using sentinel lymph node biopsy as standard reference. Journal of Ayub Medical College Abbottabad. 2019;31(2):242-7.
 10. Bugti S, Sheikh AA, Qamar N, Sheikh AA. A Comparative study of pre-operative FNAC with post-operative histopathology in the diagnosis of breast lump. Pak J Surg. 2015;31(1):3-6.
 11. Shobha S, Rajashekar Y. Role of Fine needle aspiration cytology in Head and neck lesions. Indian Journal of Pathology and Oncology. 2017;4(3):408-12.
 12. Singh K, Sharma S, Dubey V, Sharma P. Role of FNAC in Diagnosis of Breast Lumps. Studies. 1995;3:8.
 13. Dahri FJ, Awan MS, Leghari AA, Khaskheli NM, Soomro I, Memon ZI. An early diagnosis of benign breast diseases. Journal of Surgery Pakistan (International). 2010;15(4):186.
 14. Devi B, Singh K, Bhardwaj S. Cytomorphological pattern of breast lesions diagnosed on fine needle aspiration cytology in a tertiary care hospital. JK Science. 2018;20(2):57.
 15. Gupta R, Dewan D, Kumar D, Sharma R. Utility of fine-needle aspiration cytology as a screening tool in diagnosis of breast lumps. International Surgery Journal. 2017;4(4):1171-5.
 16. Panjvani SI, Parikh BJ, Parikh SB, Chaudhari BR, Patel KK, Gupta GS, et al. Utility of fine needle aspiration cytology in the evaluation of breast lesions. Journal of Clinical and Diagnostic Research: JCDR. 2013;7(12):2777.
 17. Ahmad M. Prevalence of gynaecomastia in male Pakistani Population. World Journal of Plastic Surgery. 2017;6(1): 114.
 18. Singh A, Haritwal A, Murali B. Pattern of breast lumps and diagnostic accuracy of fine needle aspiration cytology: A hospital based study from Pondicherry, India. Internet J Pathol. 2011;11(2):1-6.

© 2020 Sidhwani et al.; This is an Open Access article distributed under the terms of the Creative Commons Attribution License (<http://creativecommons.org/licenses/by/4.0>), which permits unrestricted use, distribution, and reproduction in any medium, provided the original work is properly cited.

Peer-review history:
The peer review history for this paper can be accessed here:
<http://www.sdiarticle4.com/review-history/55192>