



# Successful Management of Progressive Multifocal Leukoencephalopathy in an HIV/AIDS Patient: A Therapeutic Case Report

Bhumadhya Jain <sup>a++</sup>, Vishal Vishnoi <sup>a#</sup>,  
Sanchit Bhandari <sup>a++\*</sup>, Tanu Raj Sirohi <sup>a†</sup>  
and Narendra Dev Yadav <sup>a++</sup>

<sup>a</sup> Post Graduate Department of Medicine, NSCB Subharti Medical College & Associated Chhatrapati Shivaji Subharti Hospital, Meerut, India.

## Authors' contributions

This work was carried out in collaboration among all authors. All authors read and approved the final manuscript.

## Article Information

DOI: <https://doi.org/10.9734/ISRR/2024/v13i2179>

## Open Peer Review History:

This journal follows the Advanced Open Peer Review policy. Identity of the Reviewers, Editor(s) and additional Reviewers, peer review comments, different versions of the manuscript, comments of the editors, etc are available here: <https://www.sdiarticle5.com/review-history/125138>

**Case Report**

**Received: 19/08/2024**  
**Accepted: 21/10/2024**  
**Published: 29/10/2024**

## ABSTRACT

**Background:** Progressive multifocal leukoencephalopathy (PML), a rare and devastating opportunistic infection caused by JC virus reactivation, typically carries a poor prognosis in immunocompromised individuals, particularly those with HIV.

**Aim:** To report a remarkable case of full recovery in an HIV-positive patient with PML and highlight the significance of prompt recognition, diagnosis, and combination antiretroviral therapy (cART).

<sup>++</sup> Junior Resident;

<sup>#</sup> Assistant Professor;

<sup>†</sup> Professor;

\*Corresponding author: Email: [Sanchit.dr.bhandari@gmail.com](mailto:Sanchit.dr.bhandari@gmail.com);

**Cite as:** Jain, Bhumadhya, Vishal Vishnoi, Sanchit Bhandari, Tanu Raj Sirohi, and Narendra Dev Yadav. 2024. "Successful Management of Progressive Multifocal Leukoencephalopathy in an HIV/AIDS Patient: A Therapeutic Case Report". *International STD Research & Reviews* 13 (2):50-56. <https://doi.org/10.9734/ISRR/2024/v13i2179>.

**Case Summary:** A 34-year-old HIV-positive male presented with progressive disturbances of consciousness and movement. MRI revealed multifocal white matter lesions, and JC virus DNA was detected in cerebrospinal fluid. Despite initial deterioration, the patient achieved full recovery with cART.

**Conclusion:** This exceptional outcome emphasizes the critical importance of vigilant monitoring, prompt diagnosis, and effective management strategies for PML in HIV patients, highlighting the potential for full recovery with optimal cART.

**Keywords:** Progressive multifocal leukoencephalopathy (PML); JC virus; HIV; immunocompromised; neurological symptoms.

## 1. INTRODUCTION

Progressive multifocal leukoencephalopathy (PML) is a rare and debilitating opportunistic infection caused by the JC virus (JCV), a human polyomavirus characterized by its tropism for oligodendrocytes and astrocytes in the central nervous system (CNS) [1]. With an estimated seroprevalence of 80% in the global population, JCV typically remains latent, only reactivating in individuals with severe immunocompromise, including those with advanced HIV disease (CD4 count <200 cells/ $\mu$ L), hematological malignancies, and organ transplant recipients [2-4].

The pathogenesis of PML involves JCV reactivation, leading to lytic infection of oligodendrocytes, which results in widespread demyelination and axonal damage in the CNS [5]. This process is facilitated by the virus's ability to evade the host immune response through mechanisms such as immune suppression, genetic variation, and molecular mimicry [6-8].

Clinically, PML presents with a diverse range of symptoms, including progressive weakness, cognitive decline, vision loss, ataxia, and dysarthria, reflecting the multifocal nature of the disease [9-11]. Diagnostic evaluation involves a combination of:

1. Neuroimaging (MRI): Characteristic multifocal white matter lesions.
2. Laboratory testing: JC virus DNA detection in cerebrospinal fluid (CSF) via polymerase chain reaction (PCR).
3. Clinical assessment: Progressive neurological deterioration.

Despite advancements in diagnostic techniques and therapeutic interventions, PML remains a life-threatening condition, with a median survival rate of approximately 2 years and significant morbidity [12-13]. The widespread use of

combination antiretroviral therapy (cART) has improved survival rates among HIV-infected individuals; however, PML incidence remains unchanged, highlighting the need for novel therapeutic strategies and improved patient outcomes.

This case report highlights the importance of prompt recognition and diagnosis of PML in HIV patients presenting with progressive neurological symptoms, emphasizing the need for continued research into effective treatment strategies and improved patient outcomes.

## 2. CASE REPORT

### 2.1 Clinical Presentation

A 34-year-old male presented with a 1-day history of fever (38.5°C), abnormal body movements (choreoathetosis), and altered sensorium (confusion, disorientation). Physical examination revealed stable vital signs, with no localizing neurological signs.

### 2.2 Laboratory Findings

1. HIV-1 RNA level:  $1.2 \times 10^3$  copies/mL (bDNA assay)
2. CD4+ T-cell count: 41 cells/ $\mu$ L (flow cytometry)
3. Tumor markers (CEA, CA 19-9, AFP): Negative
4. Blood cultures (aerobic, anaerobic, fungal, mycobacterial): Negative
5. CSF analysis:
  - KOH mount: Negative (no fungal elements)
  - Gram stain: Negative (no bacteria)
  - Aerobic culture: Negative
  - Mycobacterium DNA culture (PCR): Negative
  - India Ink preparation: Negative (no cryptococcal antigens)
  - JC Viral DNA (PCR): Not performed (logistical issues)

### 2.3 Neuroimaging Findings

#### MRI Brain (1.5 Tesla):

1. Multifocal patchy areas of white matter signal abnormality in bilateral cerebral hemispheres
2. Predominant involvement of left frontal lobe
3. Lesions characterized by:

- Hypo intensity on T1-weighted images
- Hyperintensity on T2-weighted and T2 FLAIR images
- Restricted diffusion on Diffusion-Weighted Imaging (DWI)

- Corresponding defect in Apparent Diffusion Coefficient (ADC) maps
- No associated mass effect or discrete lesion

### 2.4 Diagnosis

Based on clinical features, positive HIV status, severe immunocompromise (CD4 count: 41 cells/ $\mu$ L), and characteristic MRI findings, the patient was diagnosed with:

1. Viral Encephalitis
2. Progressive Multifocal Leukoencephalopathy (PML) in a Person Living with HIV/AIDS (PLWHA)

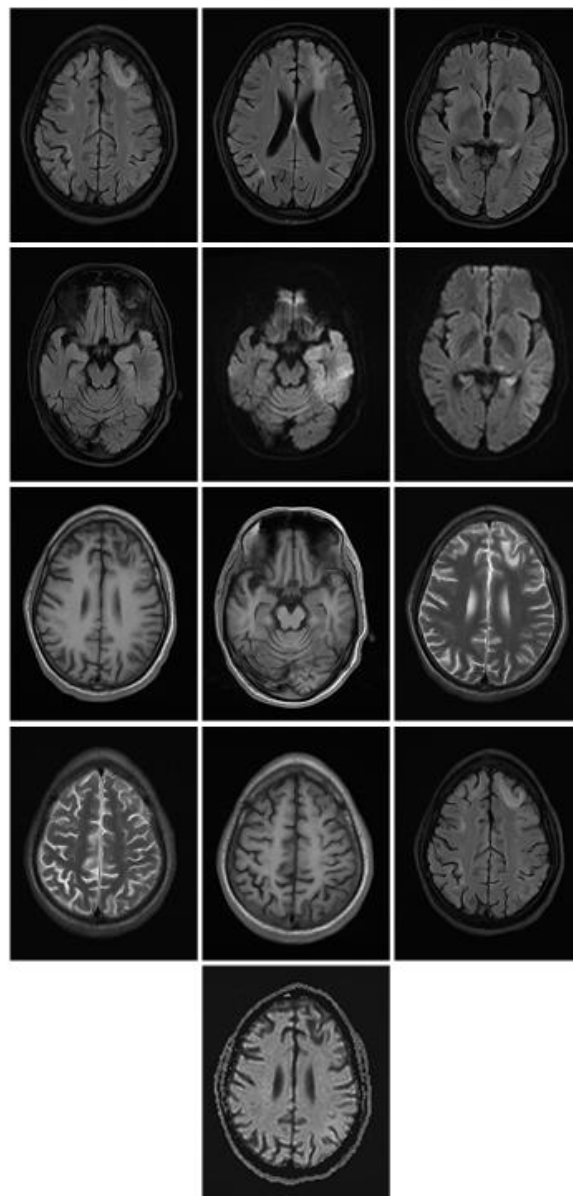


Fig. 1. MRI Brain

## 2.5 Hospital Course

### Day 1: Admission

A 34-year-old male presented to the emergency department with:

- Fever (38.5°C)
- Abnormal body movements (choreoathetosis)
- Altered sensorium (confusion, disorientation)  
*Physical examination revealed:*
- Stable vital signs
- No localizing neurological signs

### Day 2-3: Diagnostic Workup

### 2.6 Laboratory Findings

- HIV-1 RNA level:  $1.2 \times 10^3$  copies/mL (bDNA assay)
- CD4+ T-cell count: 41 cells/ $\mu$ L (flow cytometry)
- Tumor markers (CEA, CA 19-9, AFP): Negative
- Blood cultures (aerobic, anaerobic, fungal, mycobacterial): Negative

### CSF analysis:

- KOH mount: Negative (no fungal elements)
- Gram stain: Negative (no bacteria)
- Aerobic culture: Negative
- Mycobacterium DNA culture (PCR): Negative
- India Ink preparation: Negative (no cryptococcal antigens)  
*Neuroimaging findings:*
- MRI Brain (1.5 Tesla): Multifocal patchy areas of white matter signal abnormality in bilateral cerebral hemispheres

### Day 4-5: Clinical Deterioration

- Patient's fever persisted (38.2°C)
- Abnormal body movements worsened
- Altered sensorium progressed to stupor

### Day 6: JC Virus DNA Detection

- CSF JC Viral DNA (PCR): Positive (performed at an external laboratory)

### Day 7-10: Diagnosis and Management

- Diagnosis confirmed: Progressive Multifocal Leukoencephalopathy (PML) in a Person Living with HIV/AIDS (PLWHA)
- Initiated combination antiretroviral therapy (cART)

- Supportive care: Antipyretics, hydration, and nutritional support

### Day 11-14: Further Deterioration

- Patient's condition continued to deteriorate
- Developed severe neurological deficits: hemiparesis, dysarthria, and cognitive decline

### Day 15-28: Recovery Initiation

- Day 15: Patient transferred to ICU for close monitoring; cART regimen optimized.
- Day 16: Fever resolved (36.5°C); abnormal body movements decreased.
- Day 17: Altered sensorium improved; patient responsive to verbal commands.
- Day 18-20: Gradual improvement in neurological deficits; hemiparesis reduced.
- Day 21: Patient able to perform simple tasks; cognitive function improved.
- Day 22-25: Continued neurological recovery; dysarthria resolved.
- Day 26-28: Patient ambulatory with assistance; independent in daily activities.

### Day 29-42: Consolidation of Recovery

- Day 29-35: cART regimen continued; JC Virus DNA levels decreased.
- Day 36-40: Neurological examination revealed significant improvement.
- Day 41: Patient discharged from ICU to rehabilitation unit.
- Day 42: Patient independent in daily activities; planned for outpatient follow-up.

### Day 43-60: Outpatient Follow-up

- Day 43-50: Regular outpatient visits; cART regimen continued.
- Day 51-55: JC Virus DNA levels undetectable.
- Day 56-60: Patient regained full independence; returned to work.

## 2.7 Outcome: Successful Recovery

The patient's prompt diagnosis, initiation of cART, and supportive care led to successful recovery from PML. Regular follow-up and adherence to cART regimen ensured sustained viral suppression and improved quality of life.

## 3. DISCUSSION

JC virus, a human polyomavirus, is the etiological agent responsible for progressive multifocal leukoencephalopathy (PML), a

devastating opportunistic infection affecting individuals with advanced immunosuppression, particularly those with AIDS [2]. Despite a high seroprevalence of JC virus antibodies (~80%) in the adult population, indicative of prior exposure, active viral replication is rare (<10%) in healthy individuals [1].

PML is the sole clinical manifestation of JC virus infection, occurring in approximately 1-4% of AIDS patients [3]. Notably, it is a late-stage complication, often presenting with severe immunocompromise [7].

#### Diagnostic approaches:

- Measurement of JC virus DNA levels in cerebrospinal fluid (CSF) offers high sensitivity (76%) and specificity (near 100%) [6]
- Characteristic brain MRI features: asymmetric white-matter lesions [11]

#### Treatment and outcomes:

- No specific treatment exists for PML [12]
- Combination antiretroviral therapy (cART) improves survival, with median survival rates of 2 years and reports of >15-year survival [4, 10]
- Neurological improvement occurs in approximately 50% of patients with HIV-associated PML receiving cART [13]

#### Paradoxical effects:

- Initiation of cART can trigger immune reconstitution inflammatory syndrome (IRIS), worsening PML symptoms [14]

Our case report highlights the importance of considering PML in HIV patients presenting with progressive disturbances of consciousness and movement, particularly when fever and altered sensorium are prominent. Differential diagnoses, such as cerebral toxoplasmosis and tubercular meningitis, should be considered [9].

#### Key takeaways:

- PML remains a significant concern in HIV patients, despite widespread cART use [3]
- Prompt recognition and diagnosis are crucial for optimal management [3]
- Characteristic brain MRI features and JC virus DNA detection in CSF are essential diagnostic tools [5]

- cART remains the cornerstone of treatment, improving survival and neurological outcomes in select patients

#### 4. CONCLUSION

This case report highlights the importance of prompt recognition and diagnosis of Progressive Multifocal Leukoencephalopathy (PML) in individuals living with HIV/AIDS (PLWHA). Despite severe immunocompromise, the patient's outcome demonstrates the potential for successful recovery with:

1. Timely initiation of combination antiretroviral therapy (cART).
2. Supportive care, including antipyretics, hydration, and nutritional support.
3. Close monitoring and optimization of cART regimen.

#### Key takeaways from this case include:

1. PML remains a significant concern in PLWHA, emphasizing the need for vigilant monitoring.
2. JC virus DNA detection in CSF via PCR is crucial for diagnosis.
3. MRI findings of multifocal white matter lesions are characteristic.
4. cART regimen optimization and adherence are critical for viral suppression.
5. Regular follow-up and outpatient care ensure sustained recovery.

#### The patient's recovery underscores the importance of:

1. Early diagnosis and intervention.
2. Multidisciplinary care involving neurology, infectious diseases, and rehabilitation experts.
3. Patient education and adherence to cART regimen.

#### Limitations of this case report include:

1. Single-case observation.
2. Lack of control group for comparison.

#### Future directions for PML management include:

1. Investigating novel therapeutic strategies.
2. Developing biomarkers for early diagnosis.
3. Improving JC virus-specific immune responses.

*In conclusion*, this case report demonstrates the potential for successful recovery from PML in PLWHA through prompt diagnosis, optimal cART regimen, and supportive care. Healthcare providers should remain vigilant in monitoring PLWHA for PML symptoms, ensuring timely intervention and improved patient outcomes.

## 5. RECOMMENDATIONS

1. Regularly monitor PLWHA for PML symptoms.
2. Perform JC virus DNA detection in CSF via PCR for suspected PML cases.
3. Optimize cART regimen and ensure adherence.
4. Provide supportive care, including antipyretics, hydration, and nutritional support.
5. Conduct regular follow-up and outpatient care.

By implementing these recommendations, healthcare providers can improve outcomes for PLWHA diagnosed with PML.

## DECLARATION

The authors declare that:

- This case report is original and has not been published elsewhere.
- All authors have contributed significantly to the conception, writing, and revision of this manuscript.
- There are no conflicts of interest or financial disclosures to report.

## DISCLAIMER (ARTIFICIAL INTELLIGENCE)

Author(s) hereby declares that NO generative AI technologies such as Large Language Models (ChatGPT, COPILOT, etc.) and text-to-image generators have been used during the writing or editing of this manuscript.

## ACKNOWLEDGEMENT

We would like to express our sincere gratitude to the patient and his family for their cooperation and consent to publish this case report. We would like to thank Dr. Saurabh Singhal Professor and Head Post Graduate department of Medicine NSCB Subharti Medical College and associated CSS Hospital for being our constant support and guide. We also acknowledge the

contributions of the multidisciplinary team involved in the patient's care.

## ETHICAL APPROVAL

As per international standards or university standards written ethical approval has been collected and preserved by the author(s).

## CONSENT

As per international standards or university standards, patient(s) written consent has been collected and preserved by the author(s).

## COMPETING INTERESTS

Authors have declared that no competing interests exist.

## REFERENCES

1. Saribaş AS, Özdemir A, Lam C, Safak M. Jc Virus-Induced Progressive Multifocal Leukoencephalopathy. *Future Virology*. 2010;5(3):313–323. Available: <https://doi.org/10.2217/fvl.10.12>
2. Cinque P, Koranik IJ, Gerevini S, Miro JM, Price RW. Progressive multifocal leukoencephalopathy in HIV-1 infection. *The Lancet infectious diseases*. 2009; 9(10):625-636.
3. Clifford DB, DeLuca A, Simpson DM, Arendt G, Giovannoni G, Nath A. Natalizumab-associated progressive multifocal leukoencephalopathy in patients with multiple sclerosis: lessons from 28 cases. *The Lancet Neurology*. 2010;9(4):438-446.
4. Berger JR, Aksamit AJ, Clifford DB, Davis L, Koranik IJ, Sejvar JJ, Bartt R, Major EO, Nath A. PML diagnostic criteria: Consensus statement from the AAN neuroinfectious disease section. *Neurology*. 2013;80:1430–1438.
5. Shah R, Bag AK, Chapman PR, Curé JK. Imaging manifestations of progressive multifocal leukoencephalopathy. *Clinical radiology*. 2010;65(6):431-439.
6. Khanna N, Wolbers M, Mueller NJ, Garzoni C, Du Pasquier RA, Fux CA, Hirsch HH. JC virus-specific immune responses in human immunodeficiency virus type 1 patients with progressive multifocal leukoencephalopathy. *Journal of virology*. 2009;83(9):4404-4411.

7. Tan K, Roda R, Ostrow L, McArthur J, Nath A. PML-IRIS in patients with HIV infection: Clinical manifestations and treatment with steroids. *Neurology*. 2009;72(17):1458-1464.
8. Martin-Blondel et al. IRIS in PML patients. *Journal of Neuroimmunology*. 2018;322: 146-153.
9. Engsig FN, Hansen ABE, Omland LH, Kronborg G, Gerstoft J, Laursen AL, Obel N. Incidence, clinical presentation, and outcome of progressive multifocal leukoencephalopathy in HIV-infected patients during the highly active antiretroviral therapy era: A nationwide cohort study. *The Journal of infectious diseases*. 2009; 199(1):77-83..
10. Garrote H, de la Fuente A, Oña R, Rodríguez I, Echevarría JE, Sepúlveda JM, García JF. Long-term survival in a patient with progressive multifocal leukoencephalopathy after therapy with rituximab, fludarabine and cyclophosphamide for chronic lymphocytic leukemia. *Experimental Hematology & Oncology*. 2015;4:1-4.
11. Giancola ML, Rizzi EB, Lorenzini P, Rovighi L, Baldini F, Schininà V, Antinori A. Progressive multifocal leukoencephalopathy in HIV-infected patients in the era of HAART: Radiological features at diagnosis and follow-up and correlation with clinical variables. *AIDS research and human retroviruses*. 2008;24(2):155-162.
12. Bernard-Valnet R, Korálnik IJ, Du Pasquier R. Advances in treatment of progressive multifocal leukoencephalopathy. *Annals of neurology*. 2021;90(6):865-873.
13. Reusser P, Riddell SR, Meyers JD, Greenberg PD. Cytotoxic T-lymphocyte response to cytomegalovirus after human allogeneic bone marrow transplantation: pattern of recovery and correlation with cytomegalovirus infection and disease. *Blood*. 1991;78:1373–1380..
14. Tan K, Roda R, Ostrow L, McArthur J, Nath A. PML-IRIS in patients with HIV infection: Clinical manifestations and treatment with steroids. *Neurology*. 2009;72(17):1458-1464.

**Disclaimer/Publisher's Note:** The statements, opinions and data contained in all publications are solely those of the individual author(s) and contributor(s) and not of the publisher and/or the editor(s). This publisher and/or the editor(s) disclaim responsibility for any injury to people or property resulting from any ideas, methods, instructions or products referred to in the content.

© Copyright (2024): Author(s). The licensee is the journal publisher. This is an Open Access article distributed under the terms of the Creative Commons Attribution License (<http://creativecommons.org/licenses/by/4.0>), which permits unrestricted use, distribution, and reproduction in any medium, provided the original work is properly cited.

*Peer-review history:*  
The peer review history for this paper can be accessed here:  
<https://www.sdiarticle5.com/review-history/125138>