



Huge Ganglioneuroma of the Suprarenal Gland: A Surgery Case Report of a Rare Location

Rebbani Mohammed ^{a*}, Rahali Anwar ^a,
Laalou Abdelkrim ^a, El Brahmi Yasser ^a,
Njoumi Nourddine ^a, Abderrahman Elhjouji ^a,
Aziz Zentar ^a and Ait Ali Abdelmouain ^a

^a *Department of Visceral Surgery 2, HMIMV, RABAT, Morocco.*

Authors' contributions

This work was carried out in collaboration among all authors. All authors read and approved the final manuscript.

Article Information

Open Peer Review History:

This journal follows the Advanced Open Peer Review policy. Identity of the Reviewers, Editor(s) and additional Reviewers, peer review comments, different versions of the manuscript, comments of the editors, etc are available here: <https://www.sdiarticle5.com/review-history/120274>

Case Report

Received: 22/05/2024

Accepted: 25/07/2024

Published: 31/07/2024

ABSTRACT

Ganglioneuroma is a benign neoplasm that originates from neural crest cells and is characterized by well-differentiated cells such as mature Schwann cells, ganglion cells. Ganglioneuroma rarely occurs in the adrenal gland, making diagnosis challenging. Ganglioneuromas do not produce excessive catecholamines or steroid hormones, and they often remain clinically silent and asymptomatic, even when they reach a large size. The detection of this tumor has improved due to the availability of imaging techniques such as ultrasonography, computed tomography, and magnetic resonance imaging. However, histopathology remains the gold standard for confirming the diagnosis definitively and distinguishing it from a malignant tumor.

*Corresponding author: E-mail: mohammed.rebbani@gmail.com;

Cite as: Mohammed, Rebbani, Rahali Anwar, Laalou Abdelkrim, El Brahmi Yasser, Njoumi Nourddine, Abderrahman Elhjouji, Aziz Zentar, and Ait Ali Abdelmouain. 2024. "Huge Ganglioneuroma of the Suprarenal Gland: A Surgery Case Report of a Rare Location". *Asian Journal of Case Reports in Surgery* 7 (2):393-97. <https://journalajcrs.com/index.php/AJCRS/article/view/556>.

Keywords: Adrenal ganglioneuroma; computed tomography; non-secreting tumor; surgical resection.

1. INTRODUCTION

Ganglioneuroma is a benign tumor derived from the neural crest, composed of mature ganglion cells and Schwann cells. Adrenal localization and occurrence in young adults are very rare [1]. Through this case, we report a giant non-secreting ganglioneuroma of the right adrenal gland in a young individual.

2. CASE REPORT

A 17-year-old patient, with no notable medical history, presented with chronic right flank pain. Clinical examination suggested a palpable mass on lumbar contact. A CT scan revealed a right adrenal compartment mass measuring 18x13x12

cm with homogeneous tissue density and mild contrast uptake, in contact with the inferior vena cava, likely of neurogenic origin (Fig. 1). The laboratory tests were normal, ruling out a secreting mass.

The surgical exploration of our subject through laparotomy revealed a large right adrenal mass in contact with the superior vena cava and the renal vein (Fig. 2, Fig. 3). Histological examination of the specimen showed a benign tumor proliferation composed of spindle-shaped cells, with elongated nuclei without cytonuclear atypia or mitosis. This proliferation is organized in bundles with clear neural differentiation and includes mature ganglion cells in some areas, indicative of a ganglioneuroma.

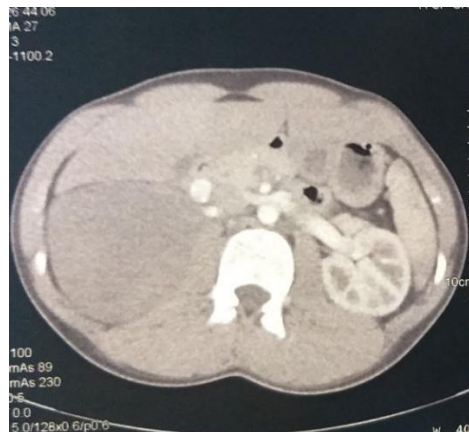


Fig. 1. Right adrenal compartment mass measuring 18x13x12 cm with homogeneous tissue density and mild contrast uptake, in contact with the inferior vena cava, likely of neurogenic origin

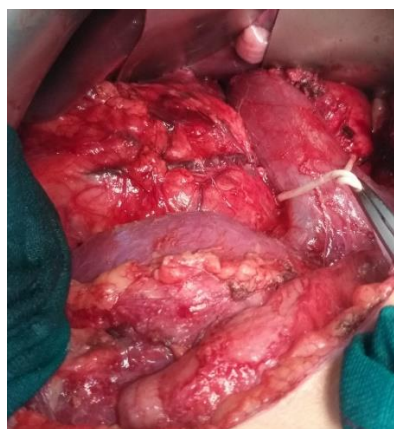

Fig. 2. Intraoperative view showing the vascular relationships where the mass is compressing the inferior vena cava and the right renal vein

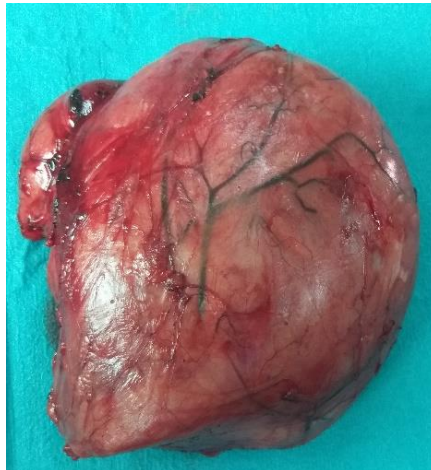

Fig. 3. Surgical specimen

3. DISCUSSION

Ganglioneuroma is a rare benign tumor of neuroectodermal origin, developed from the sympathetic nervous system. It consists of mature ganglion cells and stroma containing nerve cells associated with a Schwann cell component, unlike neuroblastoma and ganglioneuroblastoma, which are composed of more immature ganglion cells with a greater potential for progression [2]. Adrenal ganglioneuromas are more frequent in children and individuals in their fourth or fifth decade of life, and rarely in adulthood. Women are more frequently affected, with a male-to-female ratio of 0.75. The most common sites of ganglioneuromas are the retroperitoneal region (32-52%), the mediastinal region (39-43%), or the cervical region (8-9%), and only rarely in the adrenal gland [3].

Clinically, ganglioneuromas are often asymptomatic and are discovered incidentally during radiological examinations performed for other conditions. In some cases, they may present with nonspecific abdominal pain or an abdominal mass. Ganglioneuromas can compress surrounding organs, leading to various symptoms, including urinary, neurological, vascular, or digestive disorders. Typically, these tumors are non-functional, meaning they do not produce excess hormones. However, in rare cases, ganglioneuromas may secrete substances such as catecholamines or vasoactive intestinal peptide, which can cause symptoms such as diarrhea and hypertension [4]. In our case, the patient is a 17-year-old who presented with chronic pain in the right flank without any other associated symptoms.

Ganglioneuromas are typically discovered incidentally on imaging studies. Ultrasound Shows a well-defined, homogeneous, and hypoechoic mass [5]. Computed Tomography Reveals a homogeneous or slightly heterogeneous mass that often surrounds major blood vessels without compressing or occluding them. The tumor is well-defined, hypodense, and poorly enhanced by contrast medium. Calcifications are seen in approximately 42-60% of cases, with early enhancement of linear septae and delayed heterogeneous contrast uptake in some cases [6]. Magnetic Resonance Imaging T1-weighted shows a homogeneous mass with a signal intensity lower than that of the liver, while T2-weighted MRI shows a heterogeneous mass with a predominant signal intensity higher than that of the liver. T2-weighted MRI also shows no absolute change in signal intensity on chemical shift imaging. The high, heterogeneous signal intensity on T2-weighted images is presumed to be caused by a combination of the myxoid matrix and relatively low numbers of ganglion cells. These imaging characteristics are important for the diagnosis and management of patients with ganglioneuromas [7]. For our subject, the CT scan revealed a right adrenal compartment mass measuring 18x13x12 cm with homogeneous tissue density and mild contrast uptake, in contact with the inferior vena cava, likely of neurogenic origin.

The laboratory tests are only of interest in the differential diagnosis, the search for urinary metanephrines and chromogranin A allows to confirm the secreting or non-secreting nature of the lesion and to guide towards an ectopic paraganglioma. The measurement of NSE, an

enzyme expressed by neurons and cells of the APUD system ("amine precursor uptake and decarboxylation"), is useful for the diagnosis of neuroblastoma. In our case, the ganglioneuroma was non-secreting. The diagnosis of ganglioneuroma could be made thanks to a fine needle aspiration biopsy. Some authors emphasize that cytological aspiration is a less traumatic examination guiding the diagnosis [8].

The definitive diagnosis will only be made after a histological study of the surgical specimen. Indeed, complete analysis of the excised specimen is necessary due to the possibility of neuroblastoma or pheochromocytoma components within the ganglioneuroma. Surgical treatment remains the mainstay, consisting of tumor excision; a procedure that becomes more challenging when the tumor is large and has intimate relationships with adjacent structures, particularly major vessels such as the inferior vena cava and aorta. The approach is generally through a transperitoneal laparotomy, primarily for large masses. However, a laparoscopic approach remains possible and even preferred for small, well-defined retroperitoneal masses without intimate involvement with major vessels [9]. The surgical exploration of our subject through laparotomy revealed a large right adrenal mass in contact with the superior vena cava and the renal vein. Histological examination of the specimen showed a benign tumor proliferation composed of spindle-shaped cells, with elongated nuclei without cytonuclear atypia or mitosis. This proliferation is organized in bundles with clear neural differentiation and includes mature ganglion cells in some areas, indicative of a ganglioneuroma.

The progression of these tumors is slow, but an increase in volume is common in the absence of treatment. The prognosis is good with complete excision, and complications are mainly mechanical in nature. Local recurrence is rare; however, the possibility of malignant transformation into a ganglioneuroblastoma exists, highlighting the importance of prolonged surveillance [10].

4. CONCLUSION

The diagnostic approach to an adrenal incidentaloma is well established. This involves thorough endocrine exploration and assessment of radiological characteristics, which can confirm the precise diagnosis. However, in some cases,

confirmation of the diagnosis can only be achieved through histological examination, as is the case with this patient.

DISCLAIMER (ARTIFICIAL INTELLIGENCE)

Author hereby declare that NO generative AI technologies such as Large Language Models (ChatGPT, COPILOT, etc) and text-to-image generators have been used during writing or editing of manuscripts.

CONSENT

As per international standards, parental written consent has been collected and preserved by the author(s).

ETHICAL APPROVAL

As per international standards or university standards written ethical approval has been collected and preserved by the author(s).

COMPETING INTERESTS

Authors have declared that no competing interests exist.

REFERENCES

1. Juana Olivar et al. Adrenal ganglioneuroma: Clinical and surgical dilemma concerning an incidental finding. *Endocrinol Nutr.* 2013;60(10):e37-e40
2. Baïzri H, Zoubair Y, Elhadri S, Elanzaoui J, Chahbi Z, Kaddouri S, Qacif H, Touiti D, Zyani M. A hepatic cytolysis revealing an adrenal ganglioneuroma. *Pan Afr Med J.* 2014 Mar 21;17:224. French. DOI: 10.11604/pamj.2014.17.224.3744. PMID: 25170368. PMCID: PMC4145279.
3. Patel RD, Vanikar AV, Trivedi HL. Non-functional adrenal gland ganglioneuroma: case report. *Res J Endocrinol Metab.* 2013;1:1. Available: <http://dx.doi.org/10.7243/2053-3640-1-1>
4. Attafi S, et al. An unusual adrenal incidentaloma: The ganglioneuroma. *African Journal of Urology.* ISSN: 1110-5704. 2024;22(4):240-242.
5. Yamaguchi K, Hara I, Takeda M, Tanaka K, Yamada Y, Fujisawa M, Kawabat G: Two

- cases of ganglioneuroma. Urology. 2006;67:622.e1-e4.
6. Zugor V, Schott GE, Kühn R, Labanaris AP: Retroperitoneal ganglioneuroma in childhood—a presentation of two cases. Ped Neonatology. 2009;50:173–176.
 7. Majbar et al. Imaging features of adrenal ganglioneuroma: a case report. BMC Research Notes. 2014 ;7:791.
 8. Pelletier F, Manzoni P, Heyd B, et al. Retroperitoneal ganglioneuroma revealed by complicated nephretic colic. The Journal of Internal Medicine. 2006;27: 409–1.
 9. N. Rebai, A. Chaabouni, M. Bouassida, M. Fourati, K. Chabchoub, M. Hadj Slimen, M.N. Mhiri. Retroperitoneal ganglioneuroma: About 5 cases and review of the literature. African Journal of Urology. 2013;19 :215–218.
 10. Adraoui J, El Jai SR, Chehab F, Khaiz D, Bouzidi A. Retroperitoneal ganglioneuromere. Moroccan Journal of Urology. 2008;10:34–6.

Disclaimer/Publisher's Note: The statements, opinions and data contained in all publications are solely those of the individual author(s) and contributor(s) and not of the publisher and/or the editor(s). This publisher and/or the editor(s) disclaim responsibility for any injury to people or property resulting from any ideas, methods, instructions or products referred to in the content.

© Copyright (2024): Author(s). The licensee is the journal publisher. This is an Open Access article distributed under the terms of the Creative Commons Attribution License (<http://creativecommons.org/licenses/by/4.0>), which permits unrestricted use, distribution, and reproduction in any medium, provided the original work is properly cited.

Peer-review history:

The peer review history for this paper can be accessed here:

<https://www.sdiarticle5.com/review-history/120274>