

## Congenital penile curvature presenting as unconsummated marriage. Repair by 16-dot plication with subjectively reported patient and partner satisfaction

Abdel-Rahman M. Zahran, Hussein M. Abdeldaeim, Khalid Fouda & Omar F. Elgebaly

To cite this article: Abdel-Rahman M. Zahran, Hussein M. Abdeldaeim, Khalid Fouda & Omar F. Elgebaly (2012) Congenital penile curvature presenting as unconsummated marriage. Repair by 16-dot plication with subjectively reported patient and partner satisfaction, Arab Journal of Urology, 10:4, 429-433, DOI: [10.1016/j.aju.2012.09.003](https://doi.org/10.1016/j.aju.2012.09.003)

To link to this article: <https://doi.org/10.1016/j.aju.2012.09.003>



© 2012 Arab Association of Urology



Published online: 05 Apr 2019.




Submit your article to this journal [↗](#)



Article views: 352



View related articles [↗](#)



ANDROLOGY/SEXUAL MEDICINE

ORIGINAL ARTICLE

# Congenital penile curvature presenting as unconsummated marriage. Repair by 16-dot plication with subjectively reported patient and partner satisfaction

Abdel-Rahman M. Zahran, Hussein M. Abdeldaeim \*, Khalid Fouda, Omar F. Elgebaly

Department of Urology, Alexandria University, Alexandria, Egypt

Received 24 July 2012, Received in revised form 28 September 2012, Accepted 30 September 2012  
Available online 6 November 2012

## KEYWORDS

Unconsummated marriage;  
Congenital penile curvature;  
Plication;  
Outcome;  
Satisfaction

**Abstract Objective:** To evaluate self-reported patient and partner satisfaction in cases of unconsummated marriage due to congenital penile curvature that was treated by the 16-dot plication procedure.

**Patients and methods:** From March 2008 to March 2012, 24 couples presented to our institute with an unconsummated marriage due to congenital penile curvature. All patients were treated using the 16-dot plication operation. Patients were followed up for 3 months and were asked, with their partners, to complete a specific questionnaire to evaluate their satisfaction with the outcome of the operation.

**Results:** The duration of unconsummated marriage was 2–12 weeks. The mean (SD, range) angle of penile curvature was 57.4 (20.3, 30–110)°. All patients were able to consummate their marriage within a mean (SD, range) of 5.3 (1.3, 4–8) weeks after surgery. The overall satisfaction rate with the outcome of the operation among patients was nearly 100% for ‘moderately satisfied’ or greater, and among their partners was nearly 96% for ‘moderately satisfied’ or greater, at 3 months.

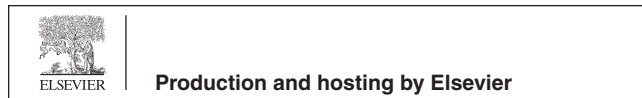**Conclusion:** The 16-dot plication technique is an easy procedure for the emergent correction of congenital penile curvature presenting as an unconsummated marriage. Most patients and their partners were pleased with the outcome of the procedure.

© 2012 Arab Association of Urology. Production and hosting by Elsevier B.V. All rights reserved.

\* Corresponding author. Tel.: +20 1223421863.

E-mail address: h\_abdeldaeim@hotmail.com (H.M. Abdeldaeim).

Peer review under responsibility of Arab Association of Urology.



## Introduction

Unconsummated marriage is a formal marital relationship in which penile penetration of the vagina did not

take place, and the situation is a source of stress for either or both spouses. In Arab countries like Egypt there is social pressure upon newly married couples to have intercourse as soon as possible, which adds to the stress of an unconsummated marriage [1,2]. Many causal factors have been reported by urologists for this condition, including erectile dysfunction, premature ejaculation, performance anxiety, hypoactive sexual desire disorder, not knowing the coital technique, and penile curvature [1,2]. However, gynaecologists consider vaginismus as the most important factor affecting difficult or impossible coitus among couples [3]. Congenital penile curvature is considered a rare condition with no evident cause [4]. Its incidence as a cause of unconsummated marriage in Egypt is unknown. Moreover, there are no reported data about the effect of penile curvature on unconsummated marriage in Arab countries. The present study was conducted to evaluate the self-reported patient and partner satisfaction in cases of unconsummated marriage due to congenital penile curvature that was treated using the 16-dot plication procedure.

### Patients and methods

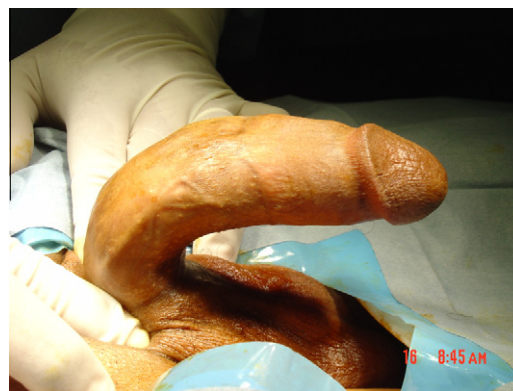This prospective study was conducted from March 2008 to March 2012 on 24 couples presenting to us with an unconsummated marriage due to congenital penile curvature. Patients with a history of previous successful sexual intercourse were excluded from the study. The mean (SD, range) patient age was 24.2 (3.4, 19–31) years and the female partner age was 21.8 (2.5, 18–26 years).

Local ethics committee approval was obtained before the beginning of the study. All couples signed an informed consent before participating in the study.

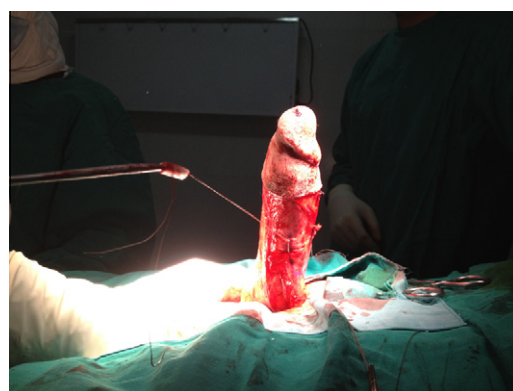
### Procedures

Patients were evaluated by a medical and sexual history, and a physical examination including a measurement of stretched penile length (with a ruler). The penile curvature was photographed by patient while he had a rigid erection. An intracavernous injection using 'bimix' (papaverine plus phentolamine) was given to all patients for an appropriate assessment of the penile curvature during a preoperative examination [5] (Fig. 1). The penile length and the angle of curvature were also measured during the examination. Patient counselling before surgery included an explanation of all possible complications and outcomes of the 16-dot plication procedure, including penile shortening, pain, numbness and subcutaneous palpation of the sutures.

The surgery was performed with the patient under spinal anaesthesia and with intravenous sedation. The plication procedure was done using nonabsorbable sutures (2/0 polyester fibre) as described by Gholami and



**Figure 1** A case of ventral curvature after intracorporeal injection.



**Figure 2** An intraoperative view showing the penis becoming straight during plication.

Lue [6], after an injection with 60 mg papaverine into the corpus cavernosum. A subcoronal circumcising incision was made, and then the centre of curvature was marked using a marking pen. Entry and exit points of the suture were also marked. Plication sutures were then placed through the full thickness of the tunica albuginea. Sutures were tied once the straightness of the penis was confirmed by all the surgical team (Fig. 2). The dartos fascia was then re-approximated and the skin was closed [6]. A Coban dressing was applied after surgery for 48 h. Patients were discharged on the same day, and instructed not to attempt sexual intercourse during the first 4 weeks after surgery. They were also advised to apply ice-packs whenever they had painful nocturnal erections. Patients were followed up for 3 months, and then patients and their female partner were asked to complete a specific questionnaire separately, to evaluate the outcome of the procedure and patient/partner satisfaction (Appendix).

### Results

The mean (SD, range) duration of the unconsummated marriage was 6.6 (3.3, 2–12) weeks. The direction of

**Table 1** The responses to the questionnaire by the 24 patients and their female partners.

Question number	Yes	No
<i>Patients</i>		
1	0	24
2	24	0
2a	0	24
3	24	0
4	24	0
5	20	4
6		
Very satisfied	20	
Moderately satisfied	4	
Unsatisfied	0	
<i>Female partners</i>		
1	0	24
2	24	0
3	24	0
4		
Very satisfied	19	
Moderately satisfied	4	
Unsatisfied	1	

penile curvature was ventral in 14 (58%), dorsal in four (16%) and lateral in six (25%) patients. The mean (SD, range) angle of curvature was 57.4 (20.3, 30–110)°, the preoperative penile length was 16.7 (2, 14–20) cm, and after surgery was 15.7 (1.8, 13–19) cm. The operative duration was 42 (8.8, 30–55) min. The penis was shorter after surgery in all patients, by a mean (SD, range) of 0.9 (0.3, 0.5–1.5) cm. Postoperative complications consisted of pain on nocturnal erection in 14 patients, which subsided after 2–3 weeks with the frequent use of ice compresses. Superficial penile skin necrosis occurred in one patient and healed completely at 5 weeks after surgery.

The follow-up questionnaire (Table 1) showed that all patients were able to consummate the marriage within a mean (SD, range) of 5.3 (1.3, 4–8) weeks after surgery (answer to question 4a). Four patients reported that they were not able to consummate marriage at the first attempt at sexual intercourse after surgery, because their partners had mild degrees of vaginismus (answer to question 5a). Three of these four partners were able to consummate the marriage at the second attempt after surgery. Only one couple had to consult a gynaecologist before they were able to consummate the marriage, after 8 weeks after surgery. The overall satisfaction rate among patients was nearly 100% for moderately satisfied or greater, and among their partners was nearly 96% for moderately satisfied or greater, at 3 months.

## Discussion

The present study shows that the problem of unconsummated marriage due to congenital penile curvature is underestimated in our community. It also highlights the importance of premarital sex education to prevent the occurrence of unconsummated marriage. This study

is the first Middle-East report of the surgical correction of congenital penile curvature presenting with an unconsummated marriage.

In the deformity of congenital penile curvature there is a disproportion between the corpora cavernosa and corpora spongiosum, leading to dorsal or ventral curvature, or a disproportion between the corpora cavernosa leading to lateral curvature [7]. Many techniques have been described to treat this condition.

Corporeal plication procedures are considered a simple and effective method for treating congenital penile curvature [6,8,9]. The 16-dot plication procedure has the advantage that there is no need to mobilise either the neurovascular bundle or the urethra. Also, there is no cutting through the tunica albuginea, thus helping to prevent the occurrence of postoperative erectile dysfunction [6]. To ensure a good outcome of the procedure some points must be carefully evaluated during surgery. These include a clear identification of the line of maximum curvature, and careful dissection of the suture location. Non-absorbable sutures were used because this is what is described in the original technique [6]. In this particular type of plication we did not depend on healing with secondary intention, but rather depended on the continuous and precise placement of the suture lines. The patient who had penile skin necrosis was one of the early cases in this series; the skin necrosis was probably due to an incorrect dissection of a patch of the skin, because the wrong fascial anatomical planes were entered, leading to devascularisation of the skin patch. This was considered in the subsequent cases.

Gholami et al. [6] reported a 15% recurrence rate of penile curvature after the 16-dot plication procedure, at a mean of 2.6 years of follow-up. In the present study there was no reported recurrence of curvature, probably due to the short follow-up. Also we report only cases of congenital penile curvature, with no cases of Peyronie's disease, which tend to have significant recurrence rates.

The religious and social traditions in Arab countries prohibit sexual intercourse between unmarried couples, and this is why all patients in the present study were unaware that penile curvature would be an obstacle to vaginal penetration. The lack of sex education might also be an important factor in this issue. Therefore, counselling of patients and their female partners before surgery was very important to provide appropriate expectations.

There is a high incidence of erectile dysfunction among Arab men, of up to 40% [10]; even the ancient Egyptians described impotence [11] and recorded many methods to treat erectile dysfunction. However, to our knowledge there are no published reports of the incidence of unconsummated marriage in Arab countries secondary to the presence of congenital penile curvature, and the magnitude of the problem is unknown. Also there are few reports on unconsummated marriage in general.



Zargooshi [1] reported the long-term outcome of 417 cases of failed sexual intercourse after marriage, due to erectile dysfunction, premature ejaculation, anxiety, no desire to have sex with women in men who had sex with men, vaginismus and lack of sexual experience, but he reported no cases due to congenital penile curvature. Ghanem et al. [12] reported 45 patients with unconsummated marriage due to 'honeymoon' impotence, and who were treated by the daily use of tadalafil. Hsieh et al. [8] reported the long-term outcome and satisfaction in 114 patients with congenital penile curvature treated by corporeal plication, who presented with difficulty or pain during vaginal penetration in most patients (except 17 who had no previous sexual experience and were bothered by the appearance of their penis). These authors concluded that the long-term outcome of tunical plication for managing congenital penile curvature is satisfactory and most of their patients were pleased with the outcome of the procedure [8].

In the present study most of the patients and their partners were highly satisfied with the outcome of the operation. Only one of the female partners reported being unsatisfied with the outcome, and she reported that this was due to a delay in performing sexual intercourse. All couples were able to consummate the marriage, and there were no legal problems or any request for a divorce.

Paez et al. [13] reported on the long-term outcome of 102 patients with penile curvature treated with tunical plication; 76 of them had curvature due to Peyronie's disease and 26 had congenital penile curvature. These authors reported that the long-term outcome was unsatisfactory for these patients because the result did not meet the patients' expectation. Patients with Peyronie's disease had previous experience with successful sexual intercourse and their expectations usually exceed their performance after surgery. They also might complain of some forms of erectile dysfunction, and penile shortening as a natural consequence of the Peyronie's disease. On the contrary, in the present series the patients were very satisfied with the outcome of the procedure, probably because they had no previous experience with sexual intercourse and had good erections; moreover, they were anxious about their failure to consummate the marriage, and thus after surgery they were very satisfied by being able to consummate the marriage.

The present study has the novel aspect of focusing on couples presenting for unconsummated marriage. Presentation of data on the female partner's satisfaction after the surgery is also novel. This study also adds to existing outcome data specific to the 16-dot plication technique, which is a simple procedure and easy to learn.

The limitations of the study include the use of an unvalidated questionnaire, which was designed by the authors because we found no previously published validated questionnaire addressing the aim of the study.

Consummation of marriage and answering the questionnaire by couples were taken as the endpoint of the present study, which was considered a short-term follow-up. However, the long-term follow-up of these patients is continuing and might be reported in the future.

The main recommendations of the present study are to identify the presence of congenital penile curvature when evaluating the history of cases of unconsummated marriage, and to have suitable premarital sexual education.

In conclusion, the 16-dot plication technique is an easy procedure for the emergent correction of congenital penile curvature presenting as an unconsummated marriage. Most patients and their partners were pleased with the outcome of the procedure.

### Conflict of interest

No conflict of interest to declare.

### Funding

None.

### Appendix A

#### (A) Questionnaire to the patient:

1. Have you ever had any sexual experience before marriage?  
Yes No
2. Did you know that you had penile curvature before marriage?  
Yes No
- 2a. If yes, did you know that this penile curvature will affect your ability to perform sexual intercourse?  
Yes No
3. Are you having as rigid an erection after the operation as before the operation?  
Yes No
4. Where you able to consummate marriage after surgery?  
Yes No
- 4a. If yes, after how many weeks after surgery were you able to consummate marriage?
5. Were you able to consummate marriage from the first attempt after the operation?  
Yes No
- 5a. If no, is there a reason for that?
6. Are you satisfied with the result of the operation?  
Very satisfied: Moderately satisfied: Unsatisfied

#### (B) Questionnaire to the female partner:

1. Have you ever had any sexual experience before marriage?  
Yes No

2. Were you disappointed because of the inability of your husband to perform sexual intercourse after marriage?

Yes No

3. Are you satisfied with the outcome of the operation on your husband?

Yes No

4. Were you satisfied with your ability to consummate marriage?

Very satisfied: Moderately satisfied: Unsatisfied

### References

- [1] Zargooshi J. Male sexual dysfunction in unconsummated marriage: long term outcome in 417 patients. *J Sex Med* 2008;**5**:2895–903.
- [2] Zargooshi J. Unconsummated marriage. Clarification of aetiology; treatment with intracorporeal injection. *BJU Int* 2000;**86**:75–9.
- [3] Jeng CJ. The pathophysiology and etiology of vaginismus. *Taiwan J Obstet Gynecol* 2004;**43**:10–5.
- [4] Montag S, Palmer LS. Abnormalities of penile curvature: chordee and penile torsion. *Sci World J* 2011;**11**:1470–8.
- [5] Ohebshalom M, Mulhall J, Guhring P, Parker M. Measurement of penile curvature in Peyronie's disease patients: comparison of three methods. *J Sex Med* 2007;**4**:199–203.
- [6] Gholami SH, Lue TF. Correction of penile curvature using the 16-dot plication technique: a review of 132 patients. *Arab. J Urol* 2002;**167**:2066–9.
- [7] Duckett JW. Hypospadias. In: Walsh PC, Retik AB, Vaughan Jr AJ, Wein AJ, editors. *Campbell's urology*. 7th ed. Philadelphia: WB Saunders Co; 1998. p. 2099, vol. 2.
- [8] Hsieh JT, Liu SP, Chen Y, Chang HC, Yu HJ, Chen CH. Correction of congenital penile curvature using modified tunical plication with absorbable sutures: the long term outcome and patient satisfaction. *Eur Urol* 2007;**52**:261–6.
- [9] Chien GW, Aboseif SR. Corporeal plication for the treatment of congenital penile curvature. *Arabian J Urol* 2003;**169**:599–602.
- [10] EL-Sakka AI. Erectile dysfunction in Arab countries. Part I. Prevalence correlates. *Arabian J Urol* 2012;**10**:97–103.
- [11] Shokeir AA, Hussein MI. Sexual life in Pharaonic Egypt: towards a urological view. *Int J Impot Res* 2004;**16**:385–8.
- [12] Ghanem H, El-Dakhly M, Shamloul R. Alternate day tadalafil in the management of honeymoon impotence. *J Sex Med* 2008;**5**:1451–4.
- [13] Paez A, Mejias J, Vallejo J, Romero I, De Castro M, Gimeno F. Long-term patient satisfaction after surgical correction of penile curvature via tunical plication. *Int Braz J Urol* 2007;**33**:502–9.